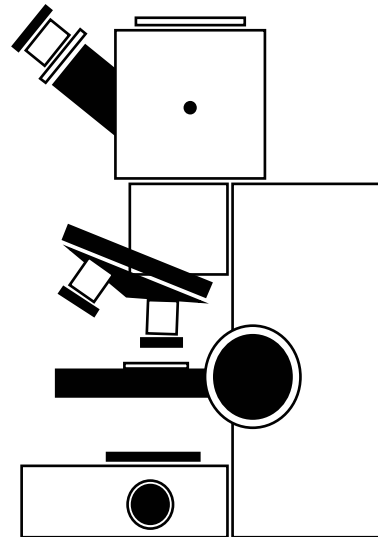


ATLAS DE MICROSCOPIA



ANATOMIA PATOLOGICA
FACULTAD DE MEDICINA

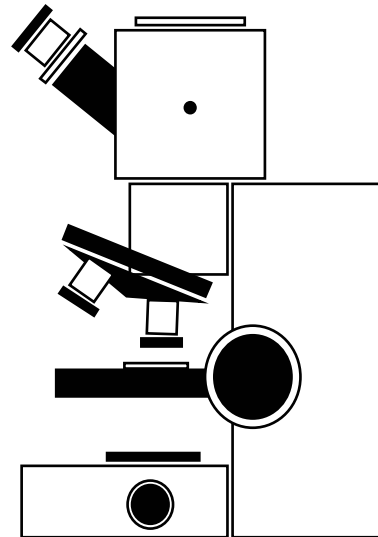


ANATOMÍA PATOLÓGICA

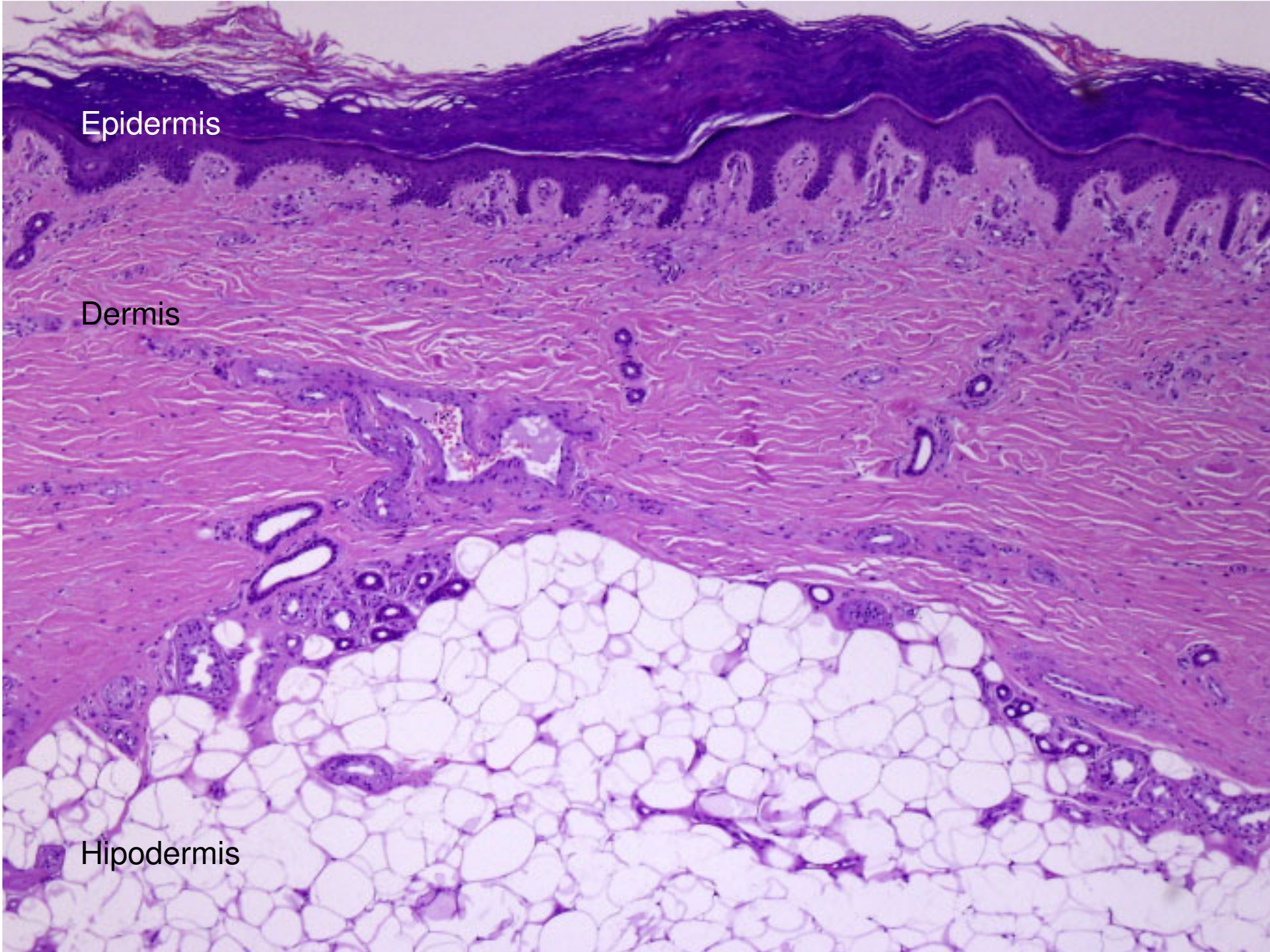
ATLAS DE MICROSCOPIA PIEL

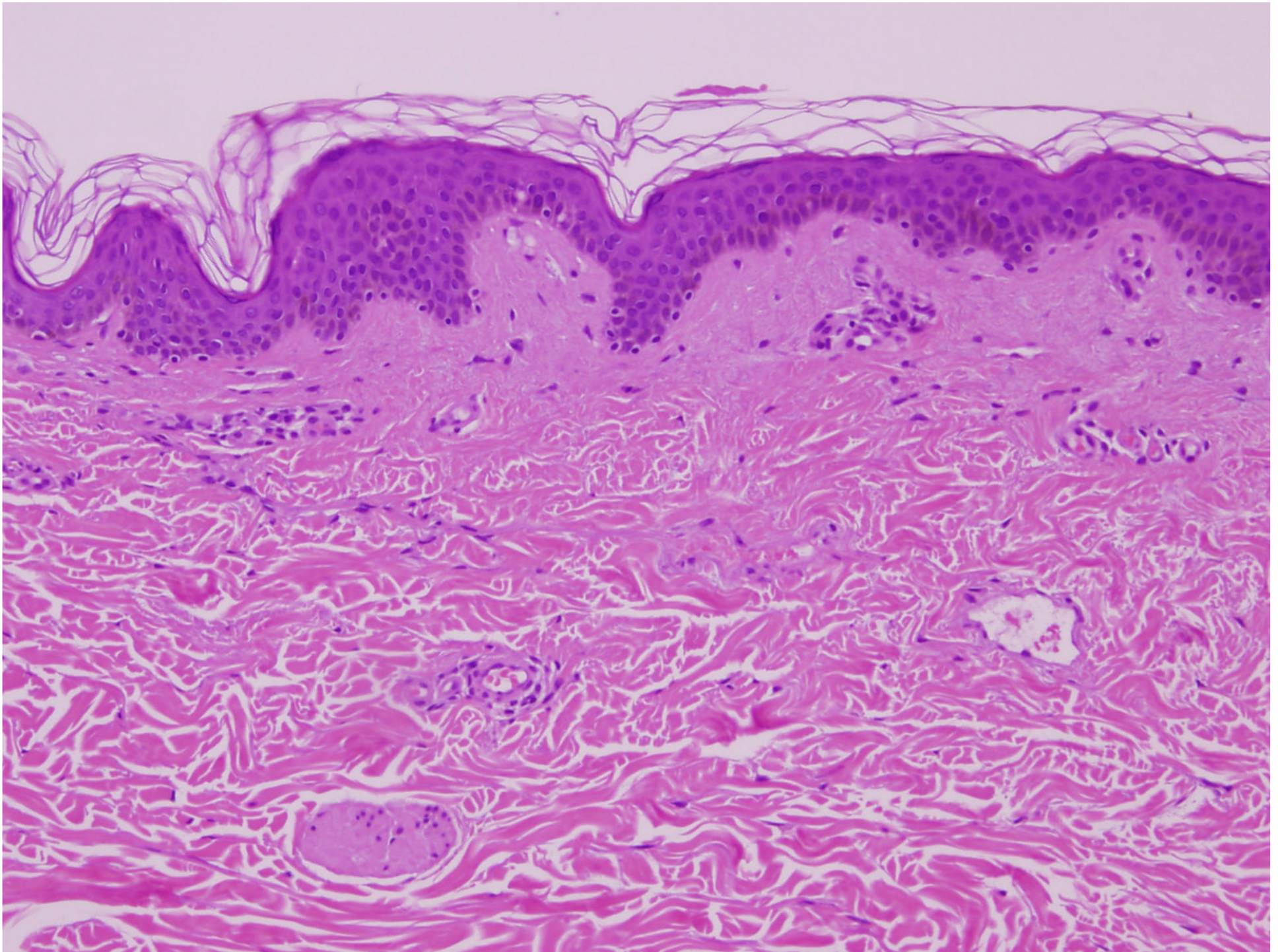


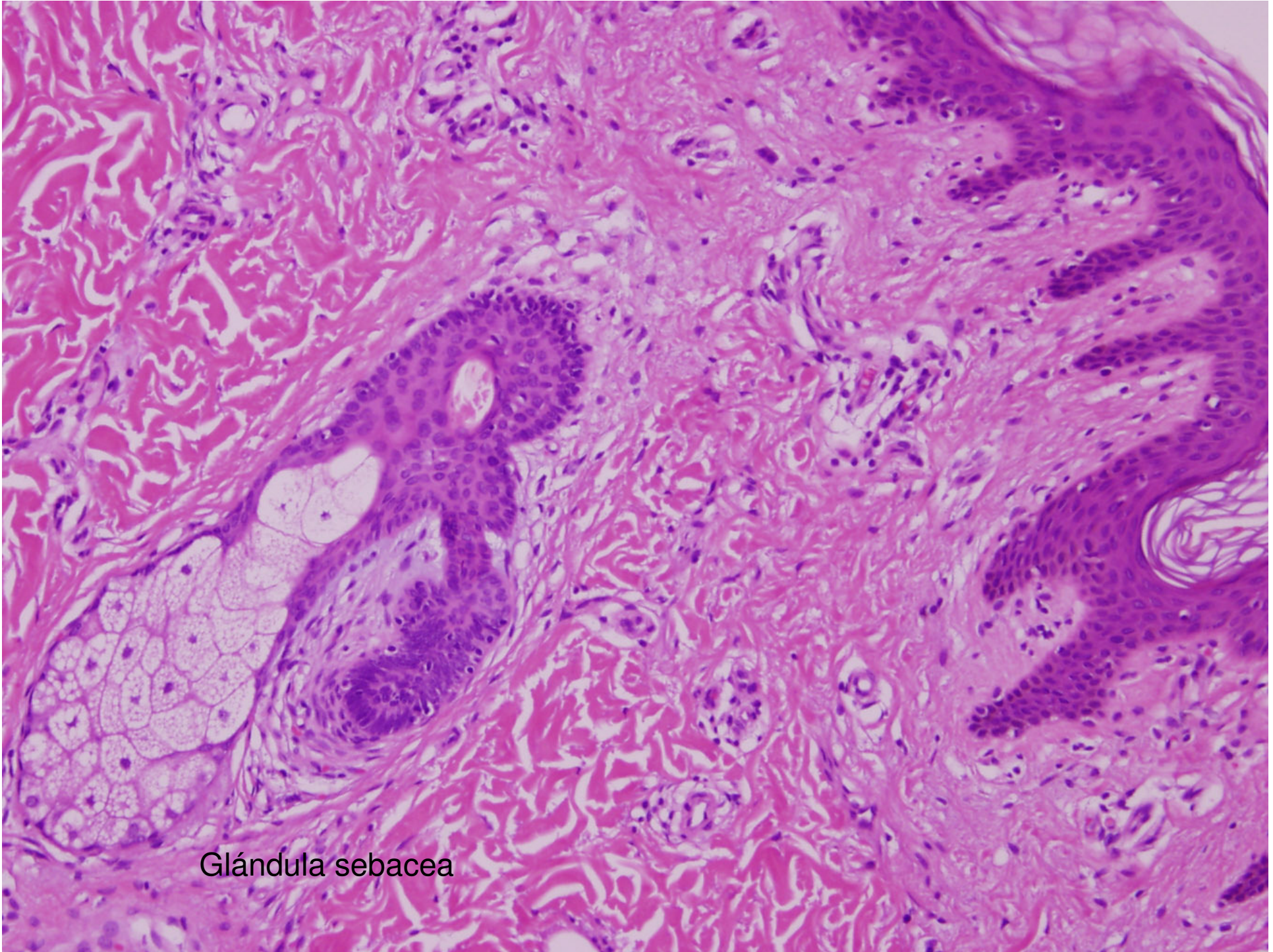
ANATOMIA PATOLÓGICA
FACULTAD DE MEDICINA



ANATOMÍA PATOLÓGICA

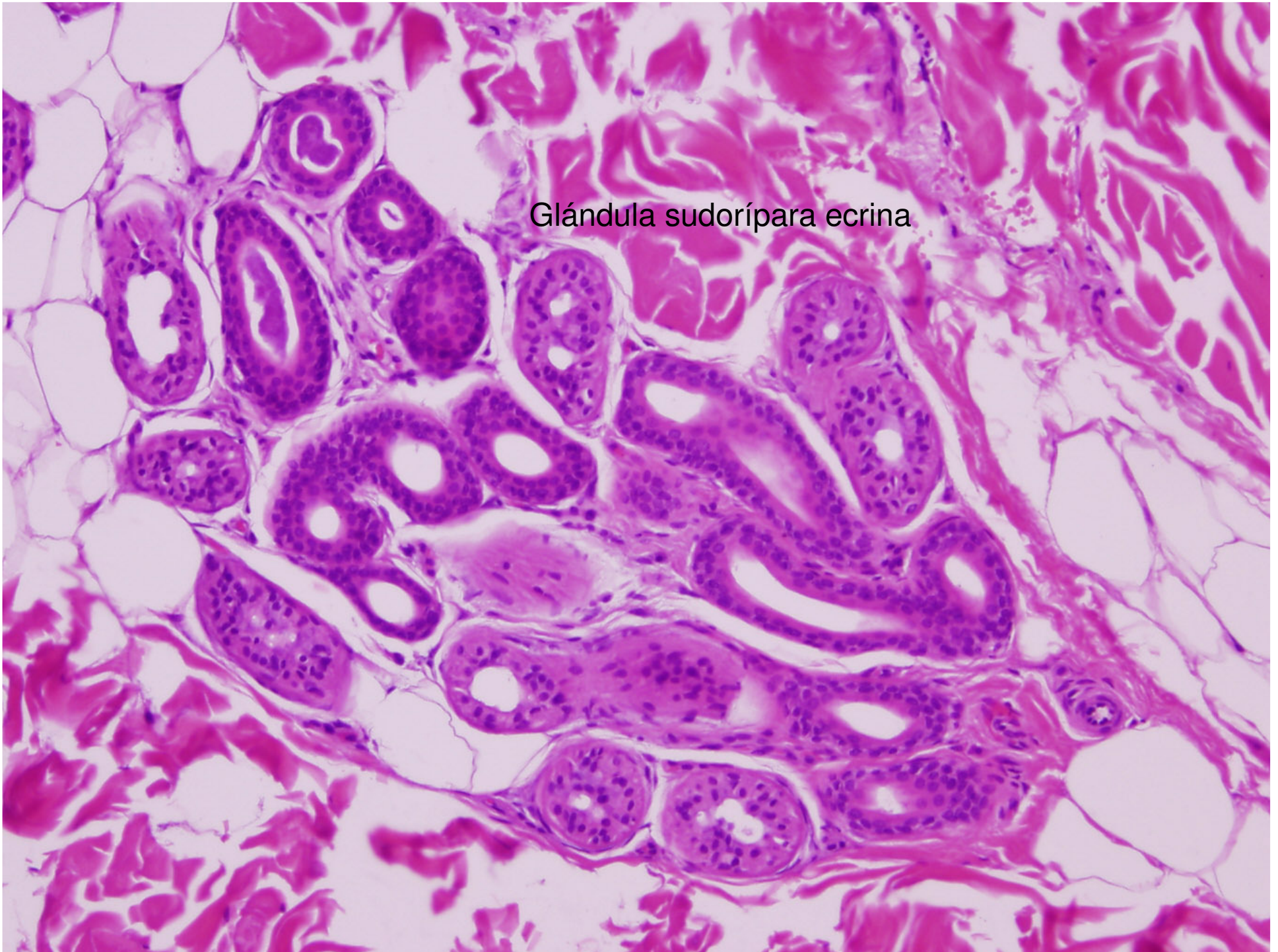






Glándula sebacea

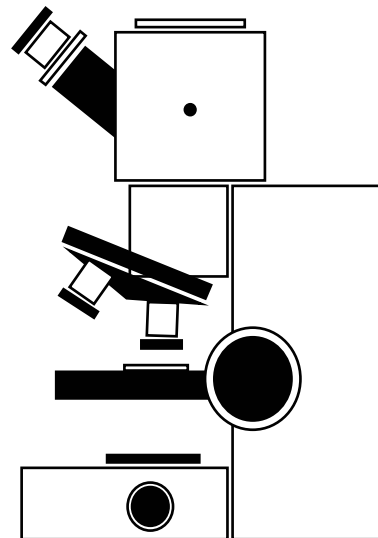
Glándula sudorípara ecrina



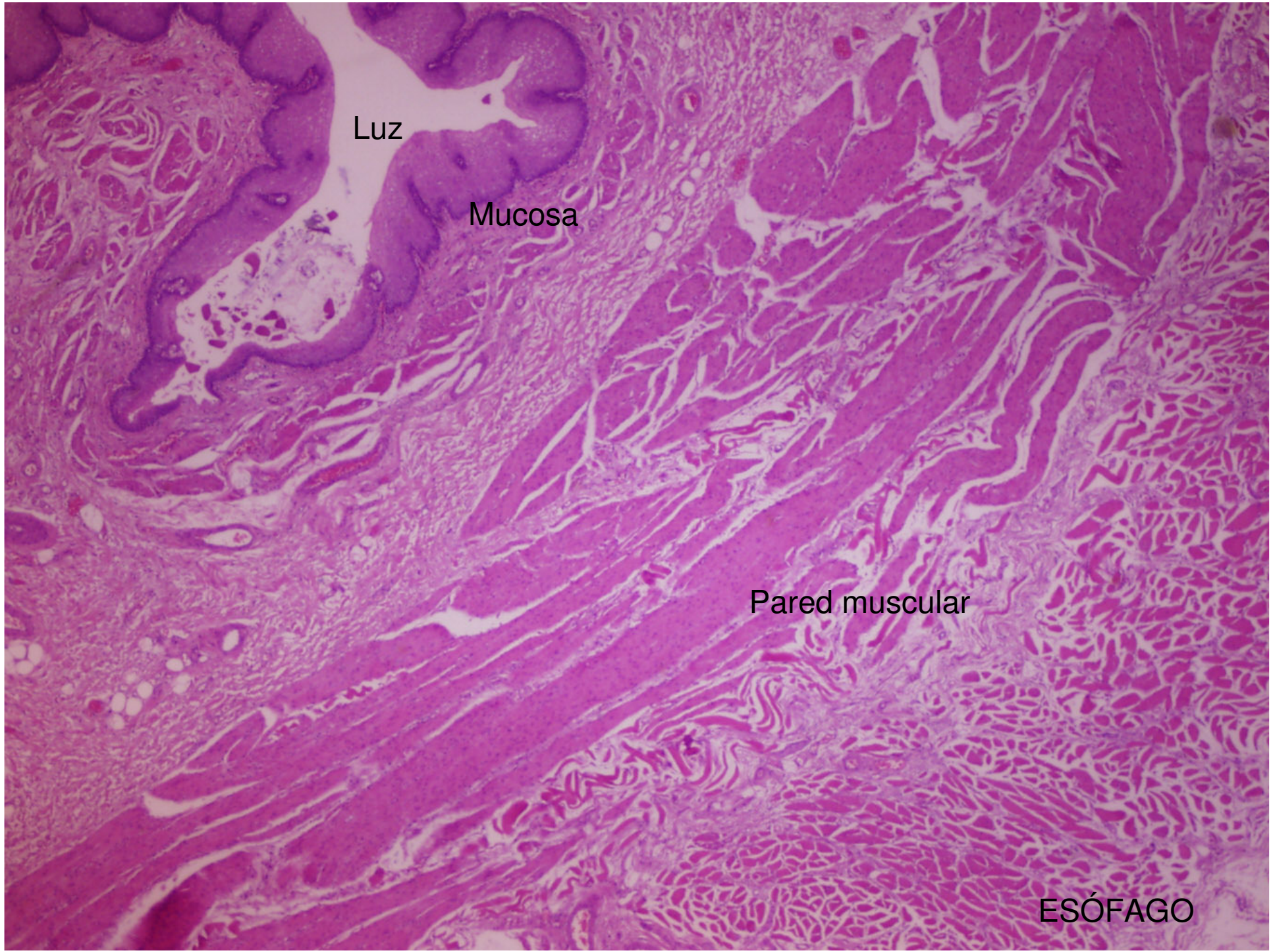
ATLAS DE MICROSCOPIA APARATO DIGESTIVO



ANATOMIA PATOLOGICA
FACULTAD DE MEDICINA



ANATOMÍA PATOLÓGICA

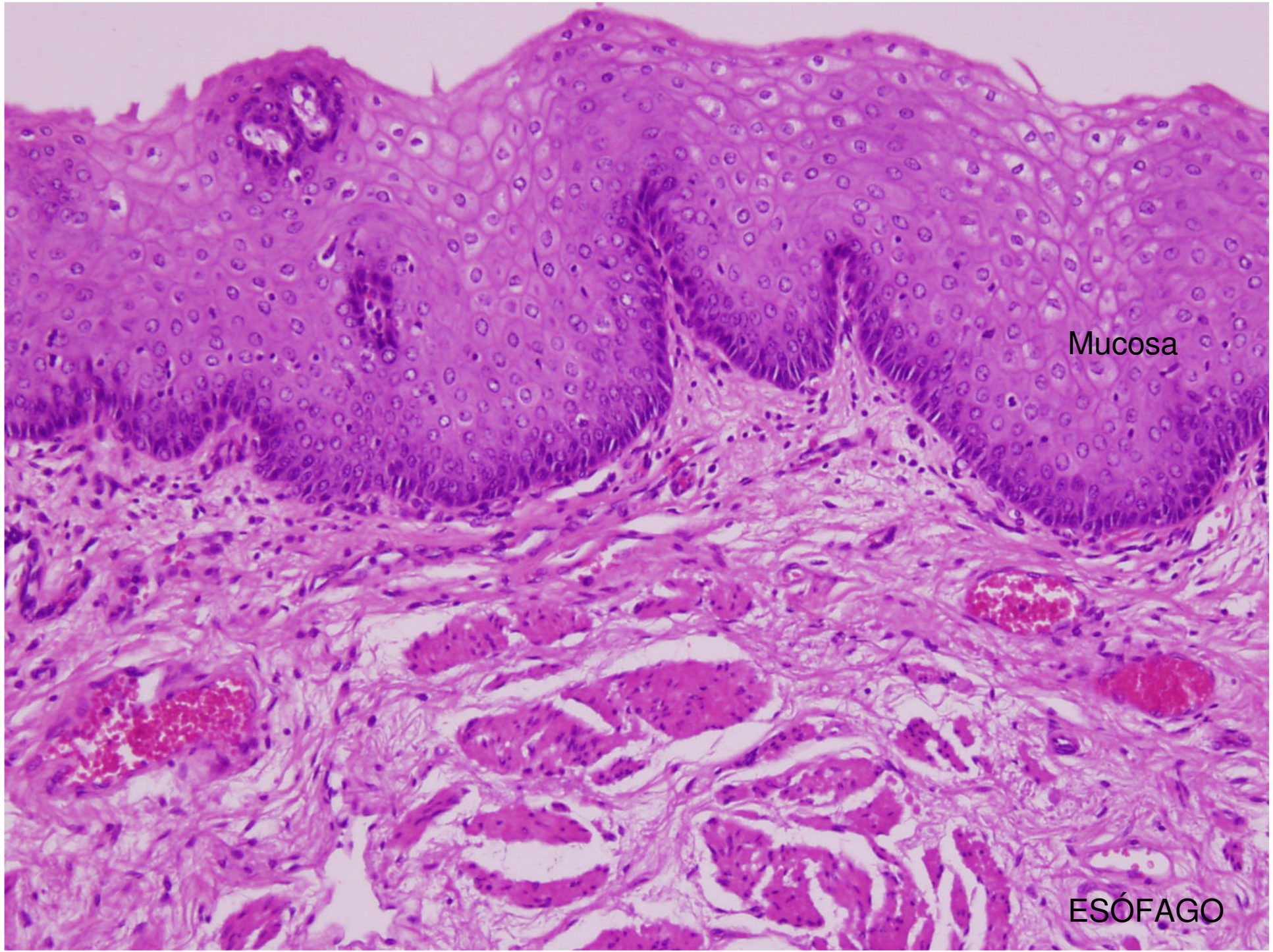


Luz

Mucosa

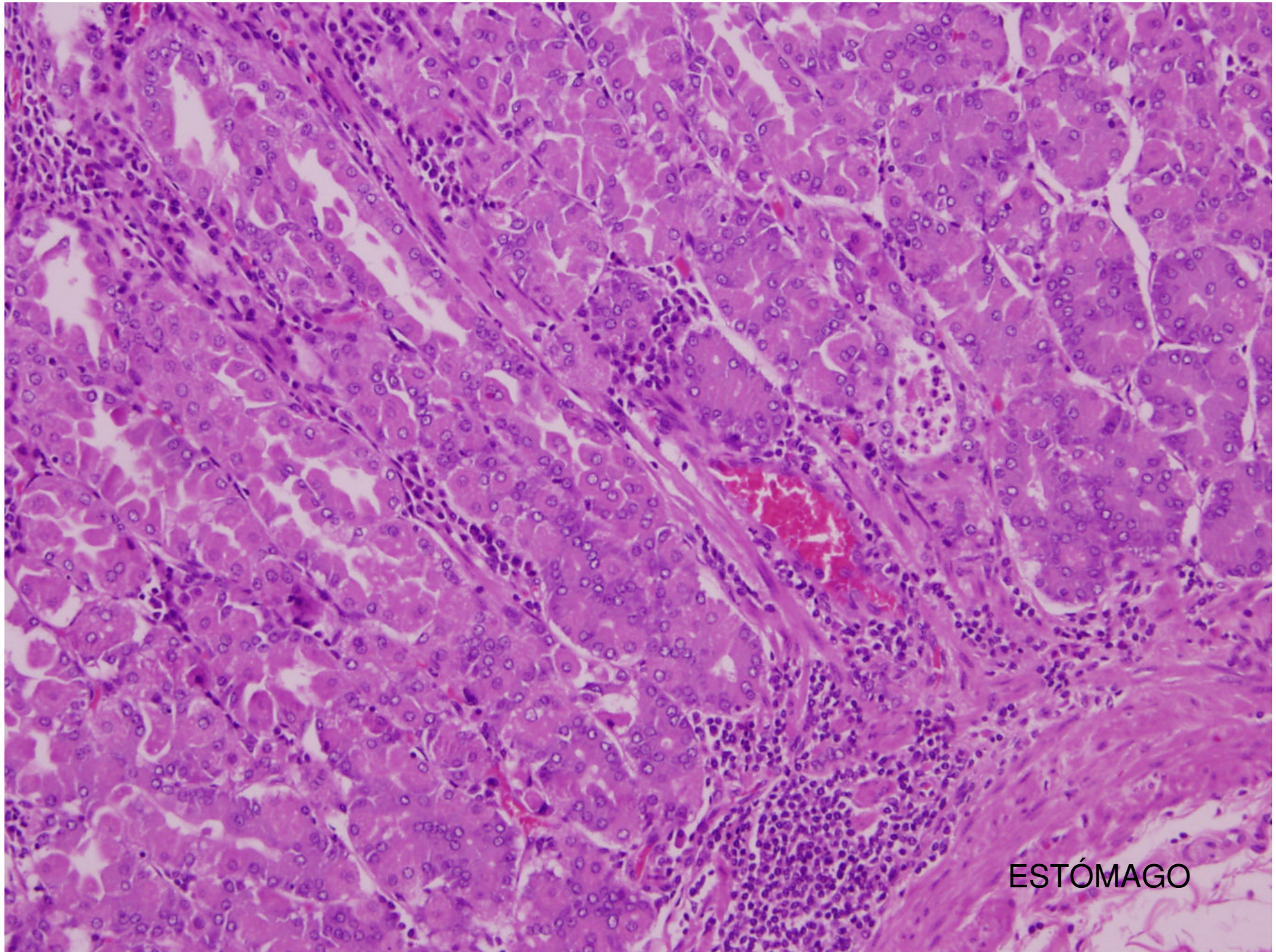
Pared muscular

ESÓFAGO

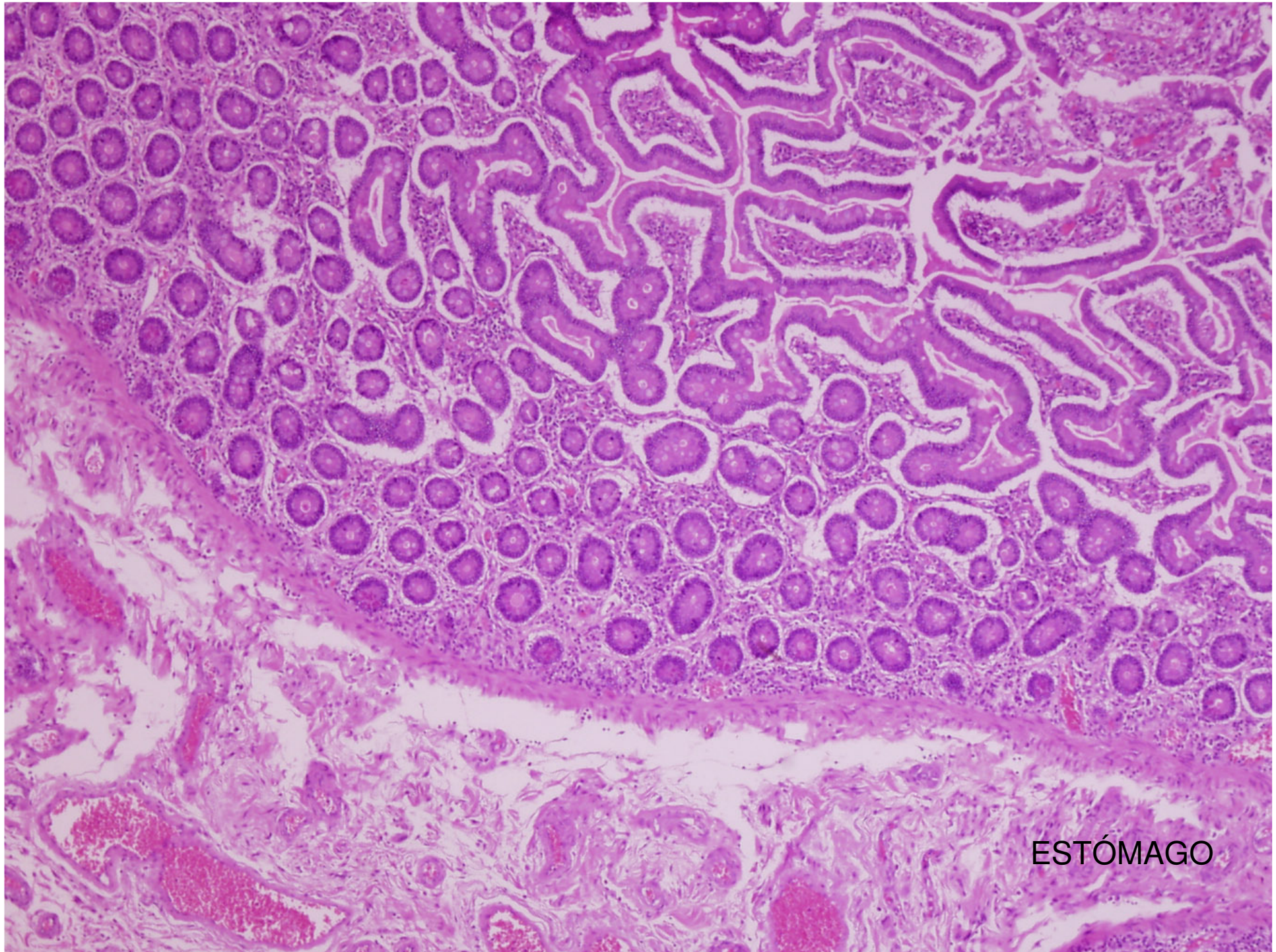


Mucosa

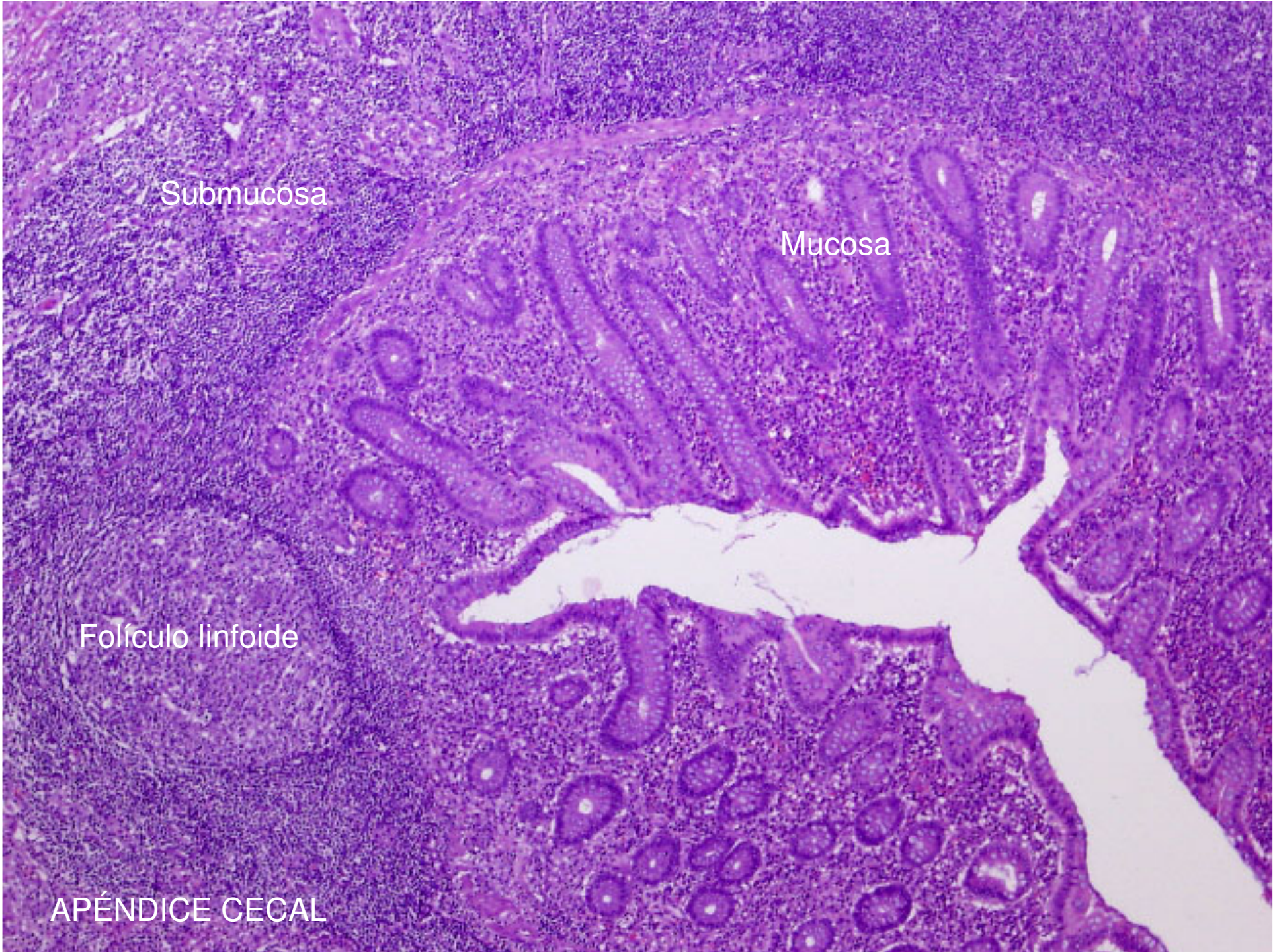
ESÓFAGO



ESTÓMAGO



ESTÓMAGO

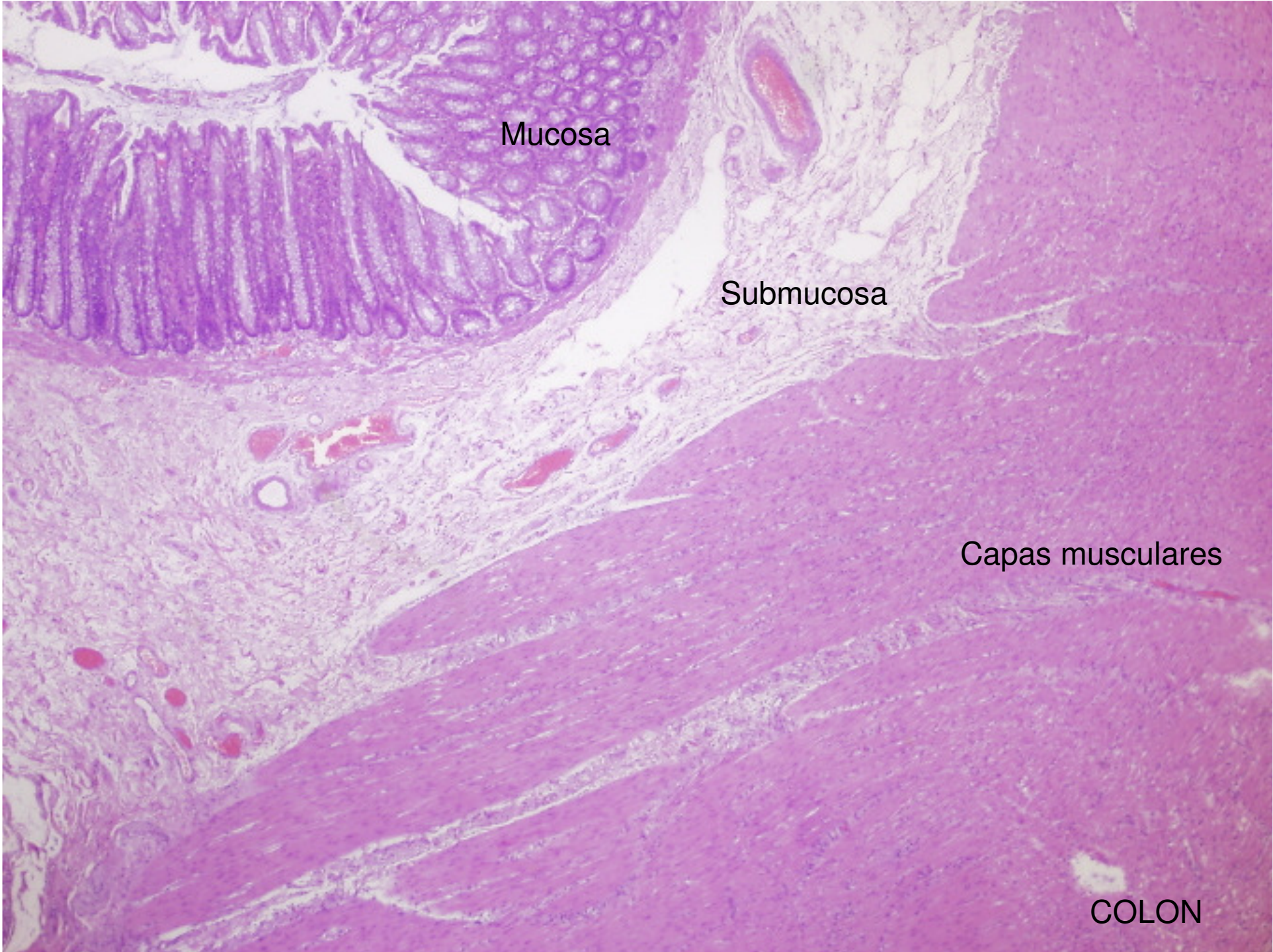


Submucosa

Mucosa

Folículo linfoide

APÉNDICE CECAL



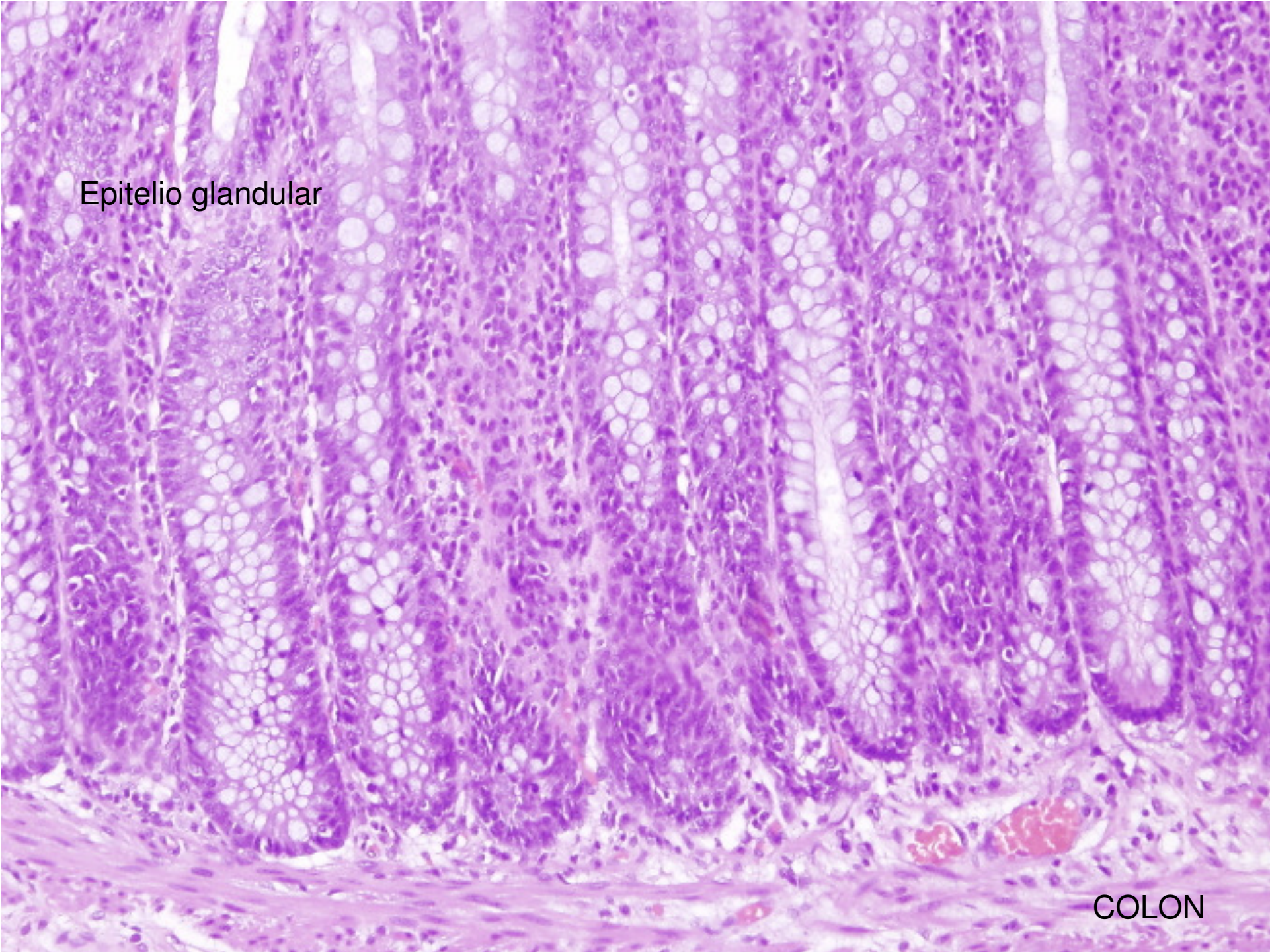
Mucosa

Submucosa

Capas musculares

COLON

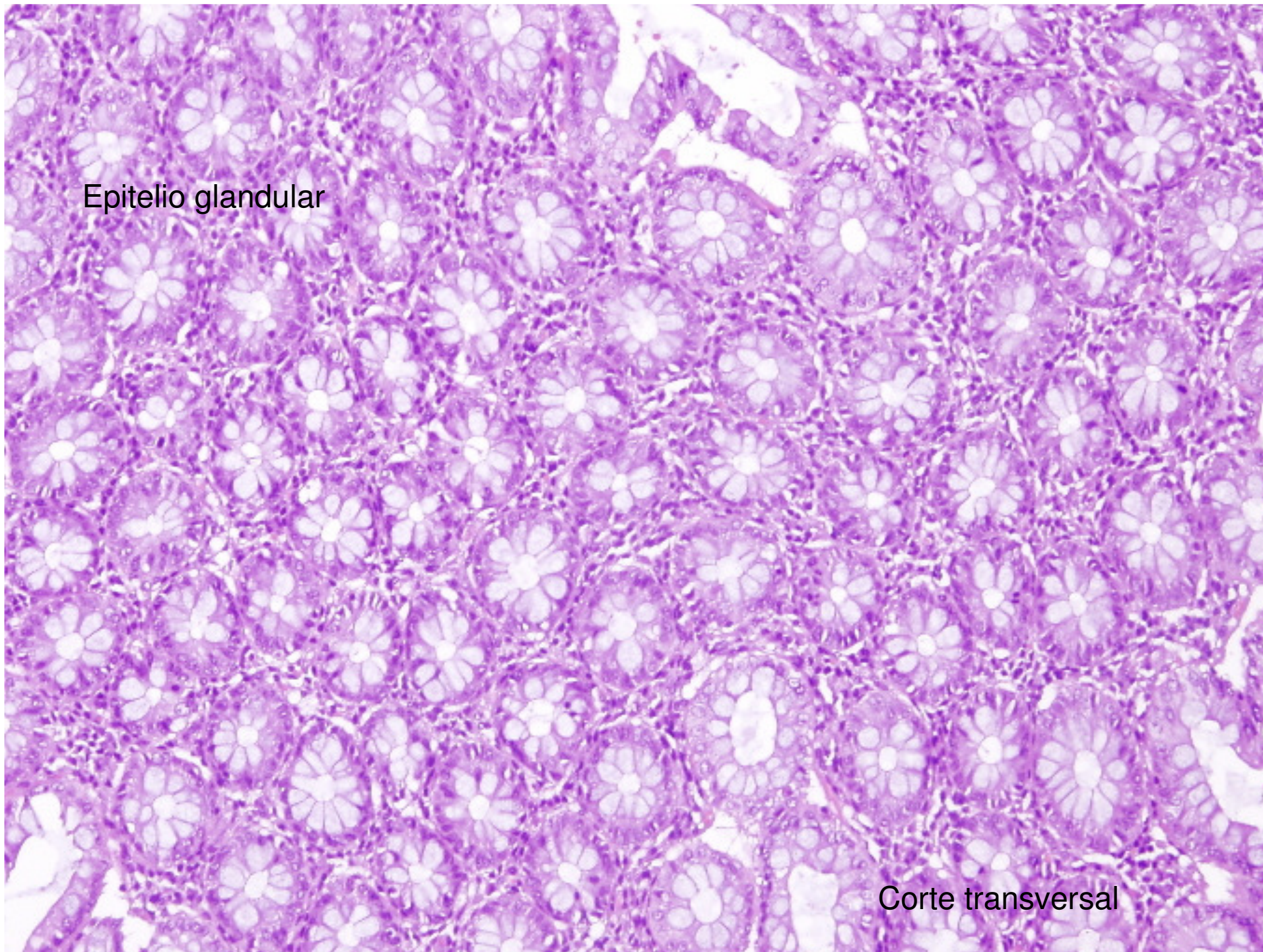
Epitelio glandular



COLON

Epitelio glandular

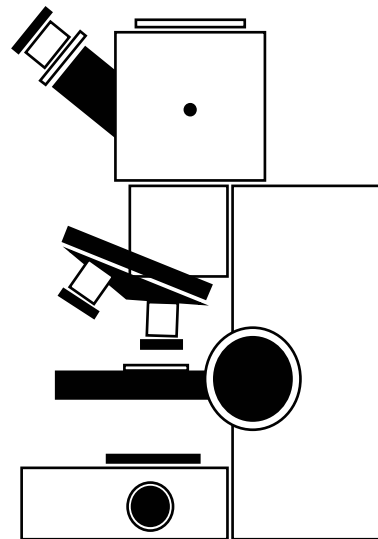
Corte transversal



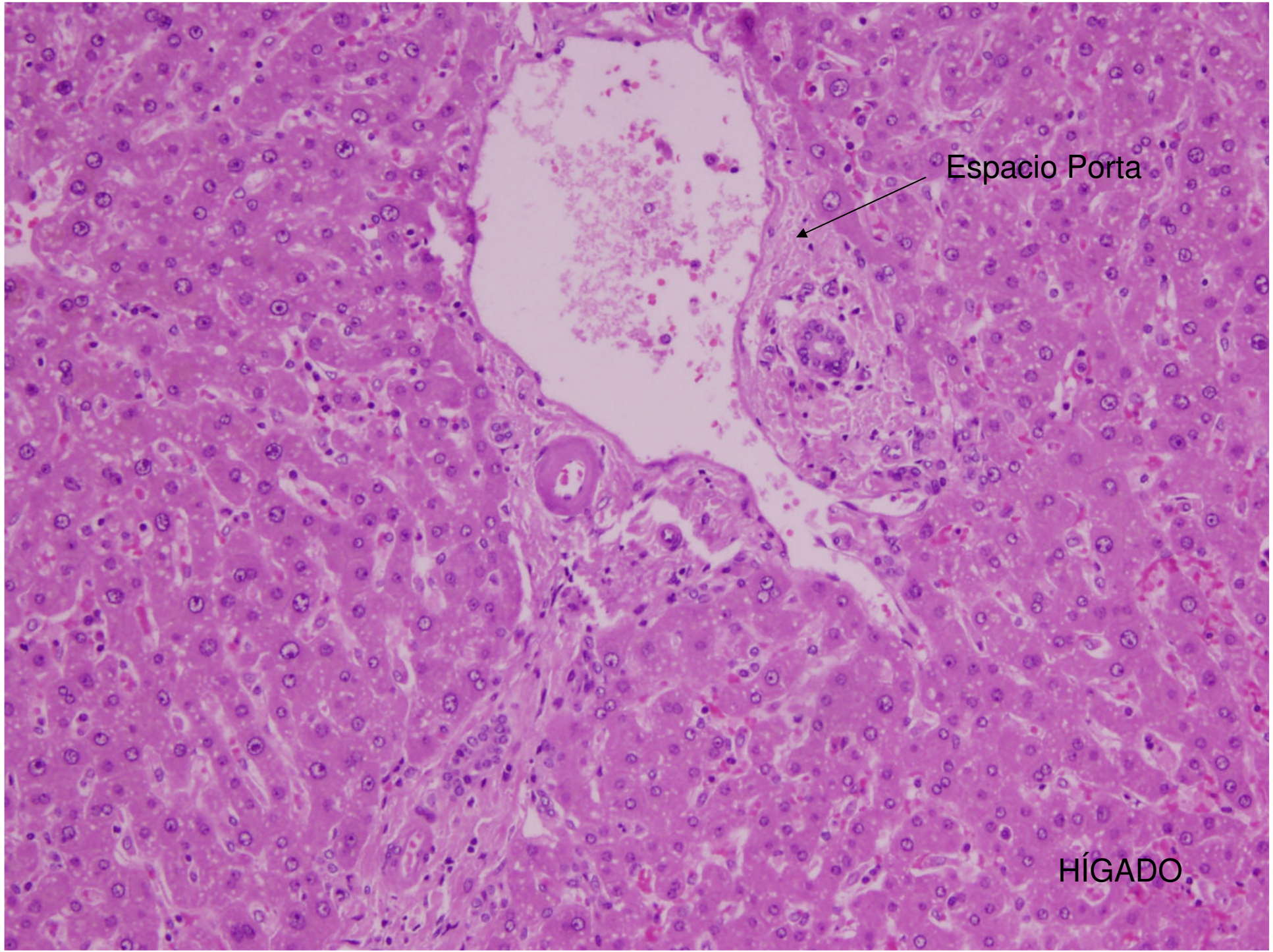
ATLAS DE MICROSCOPIA HÍGADO



ANATOMIA PATOLOGICA
FACULTAD DE MEDICINA

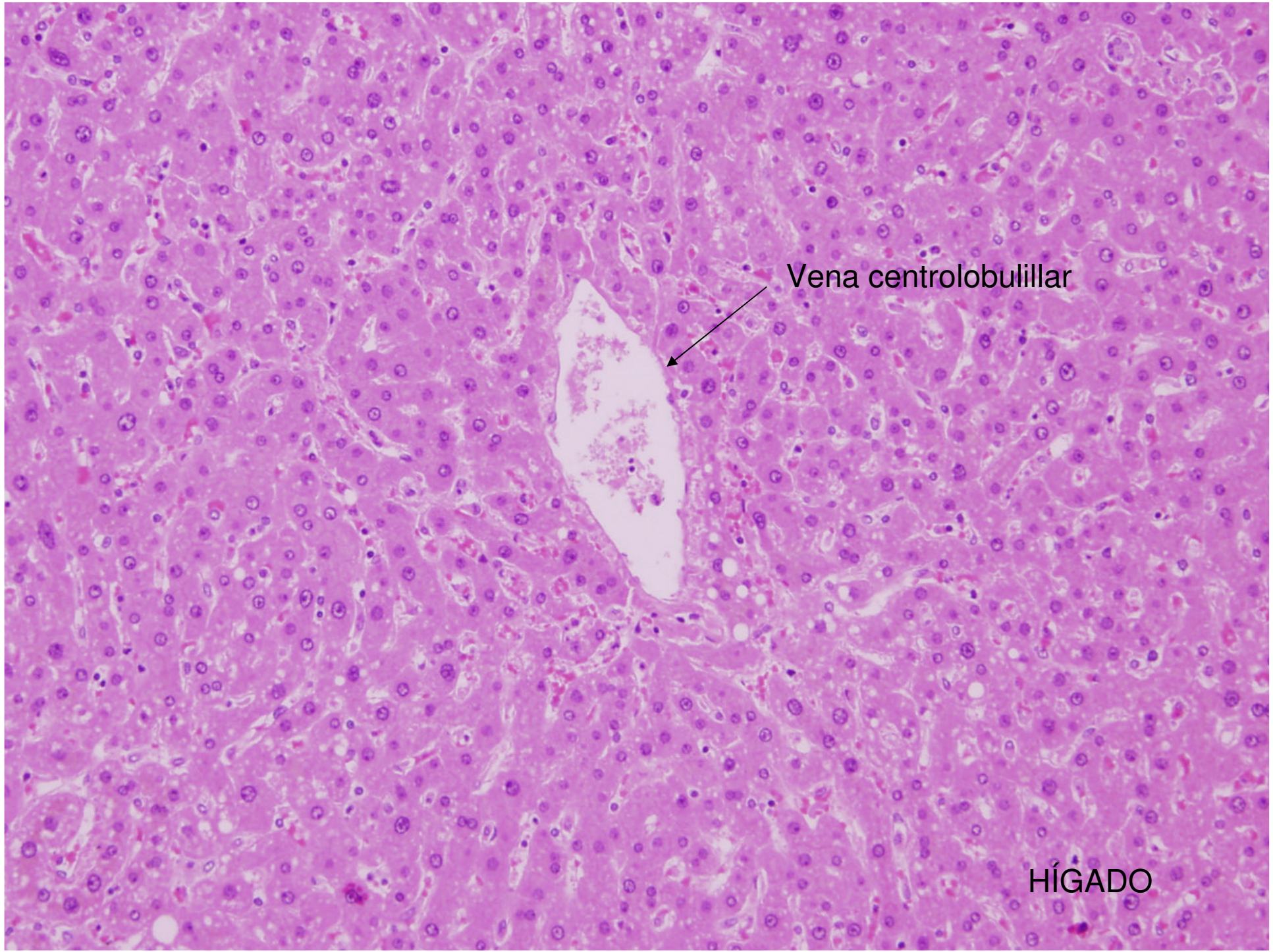


ANATOMÍA PATOLÓGICA



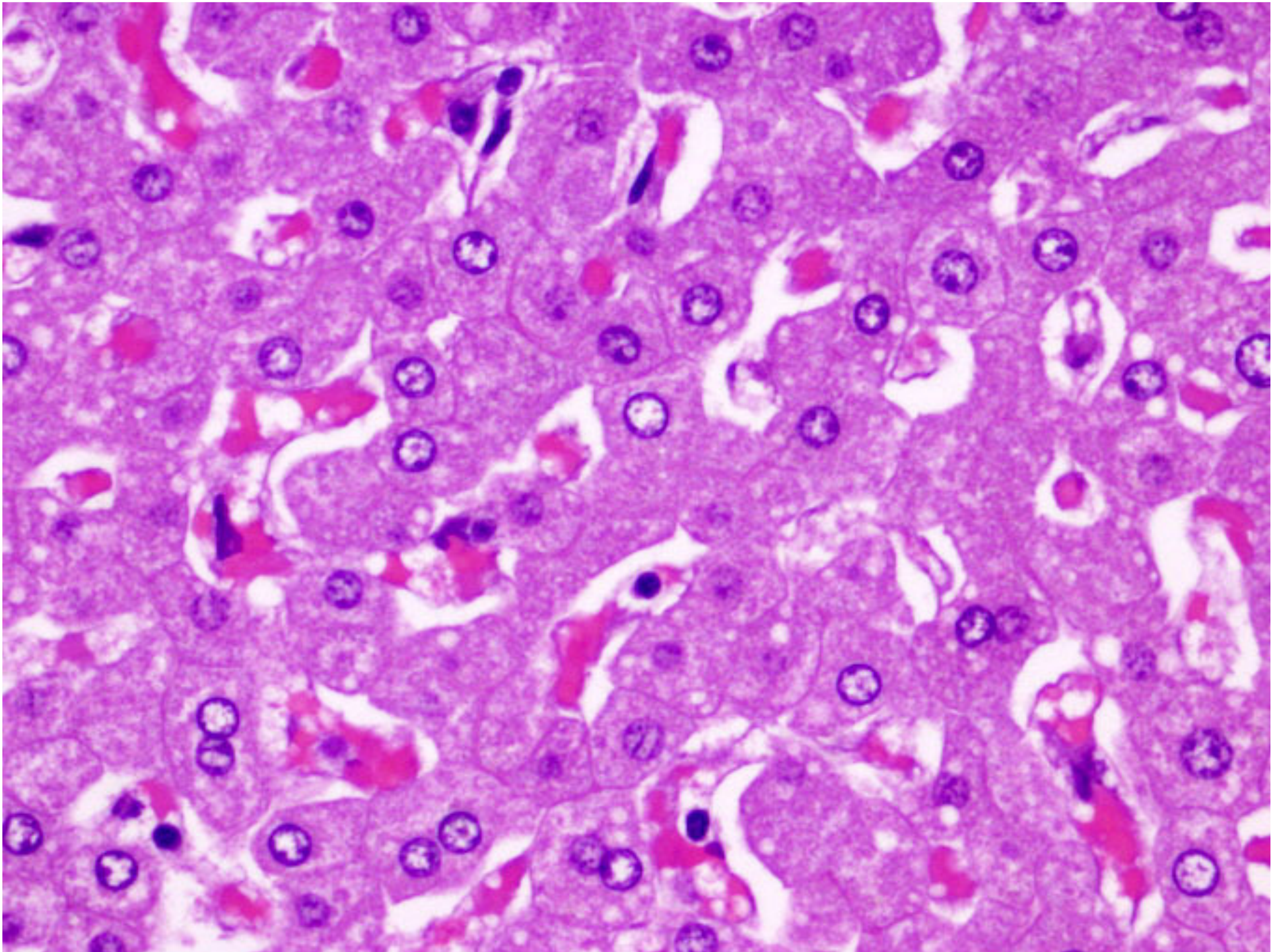
Espacio Porta

HÍGADO



Vena centrolobulillar

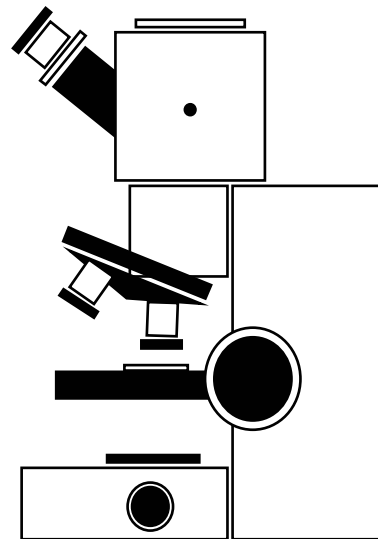
HÍGADO



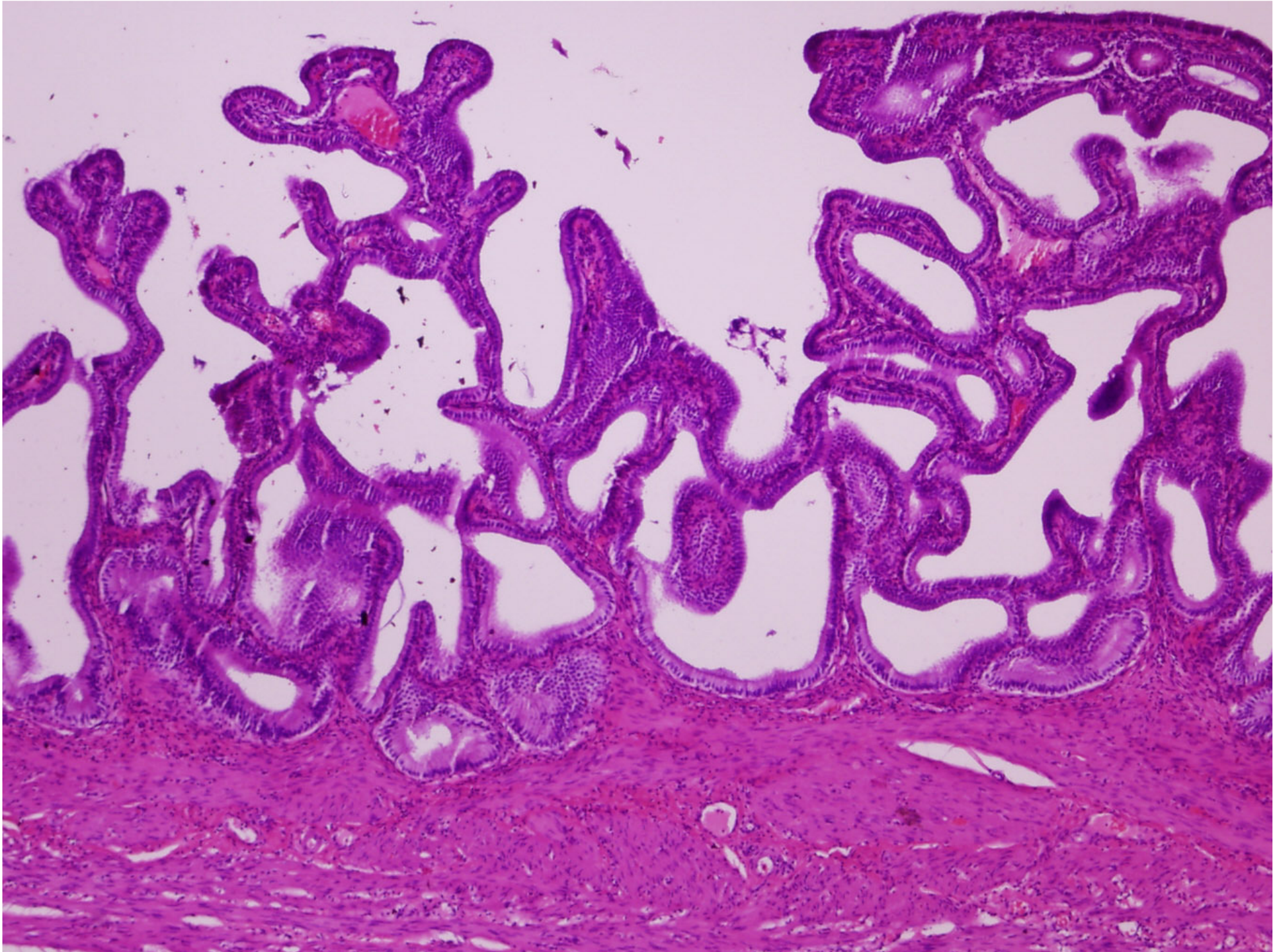
ATLAS DE MICROSCOPIA VESICULA BILIAR



ANATOMIA PATOLOGICA
FACULTAD DE MEDICINA



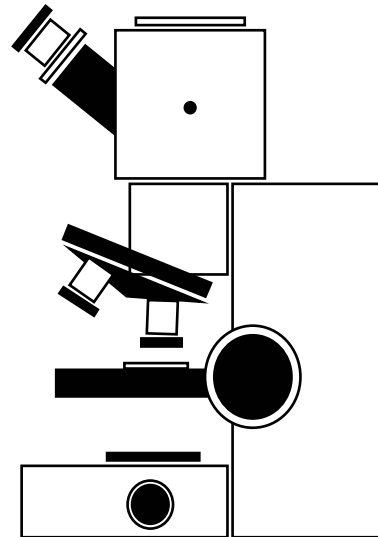
ANATOMÍA PATOLÓGICA



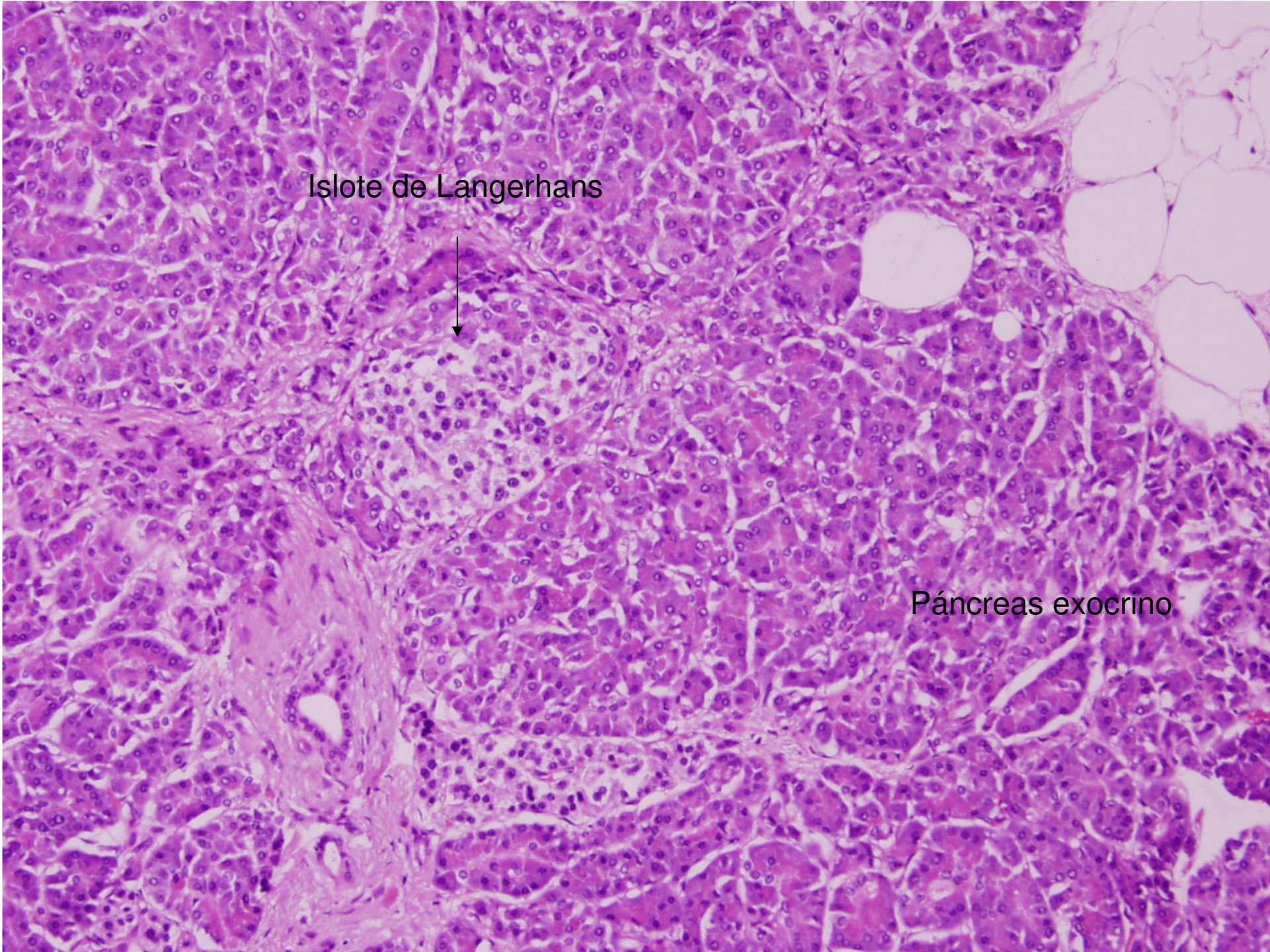
ATLAS DE MICROSCOPIA PANCREAS



ANATOMIA PATOLOGICA
FACULTAD DE MEDICINA



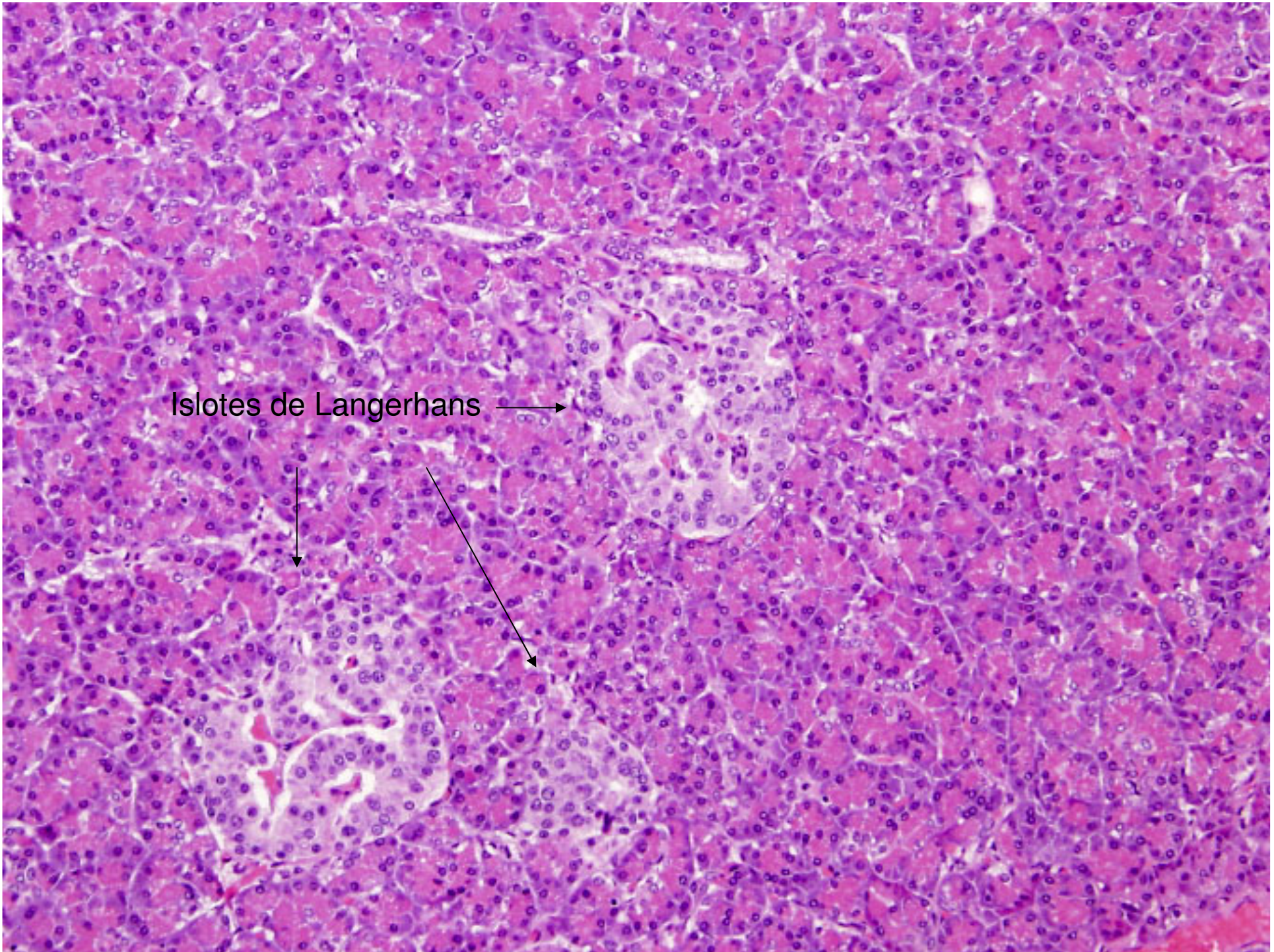
ANATOMÍA PATOLÓGICA



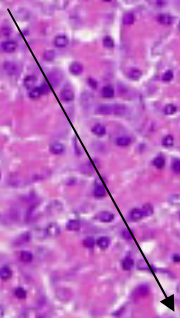
Islote de Langerhans



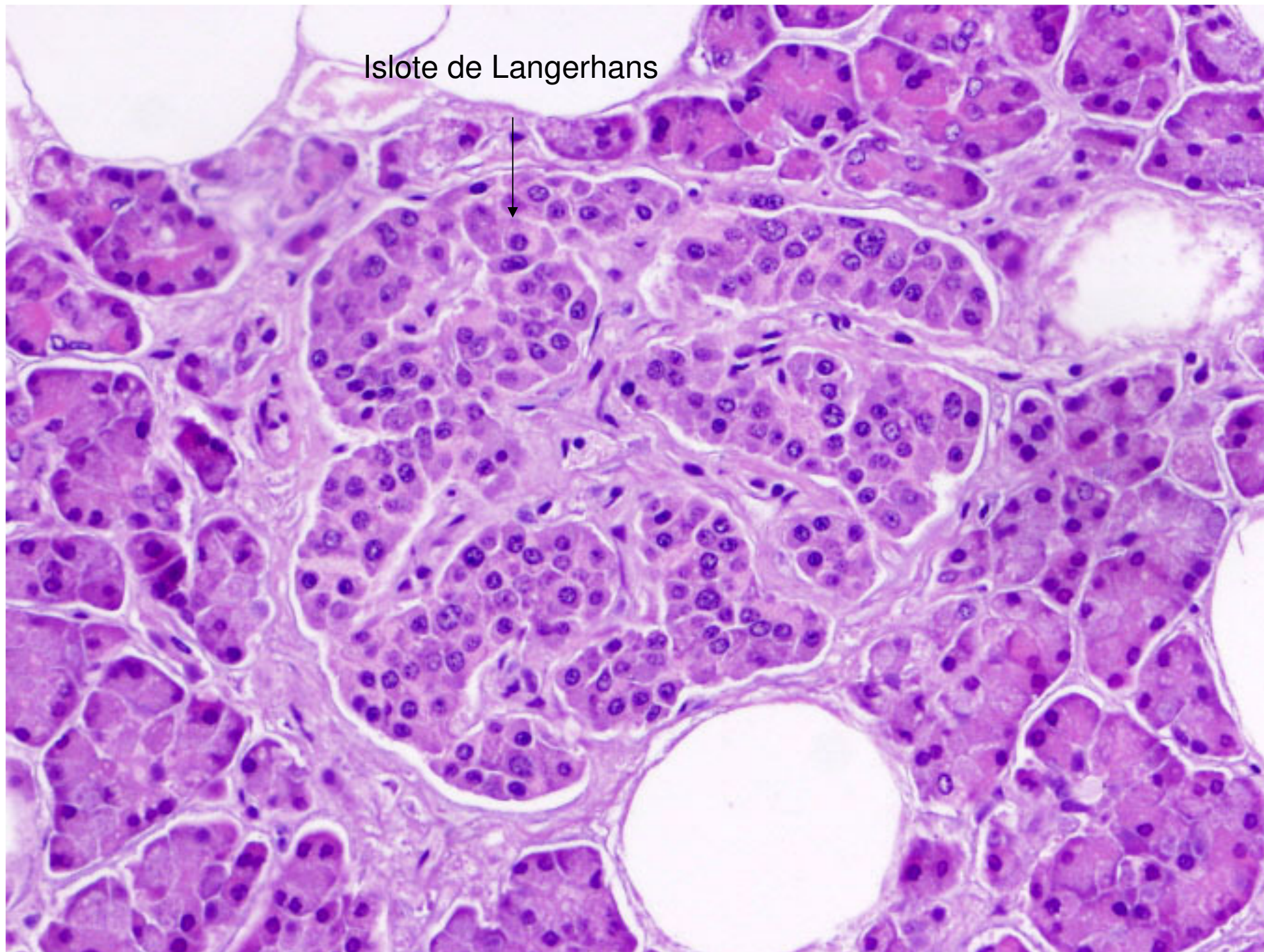
Páncreas exocrino



Islotes de Langerhans →



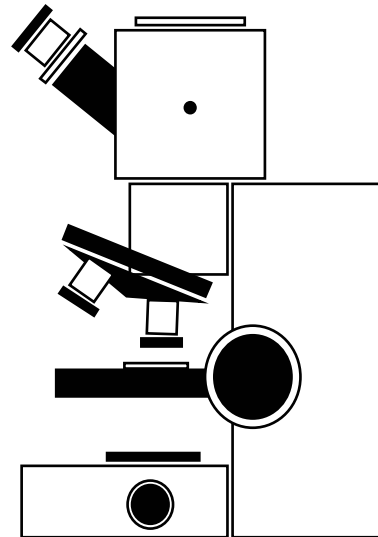
Islote de Langerhans



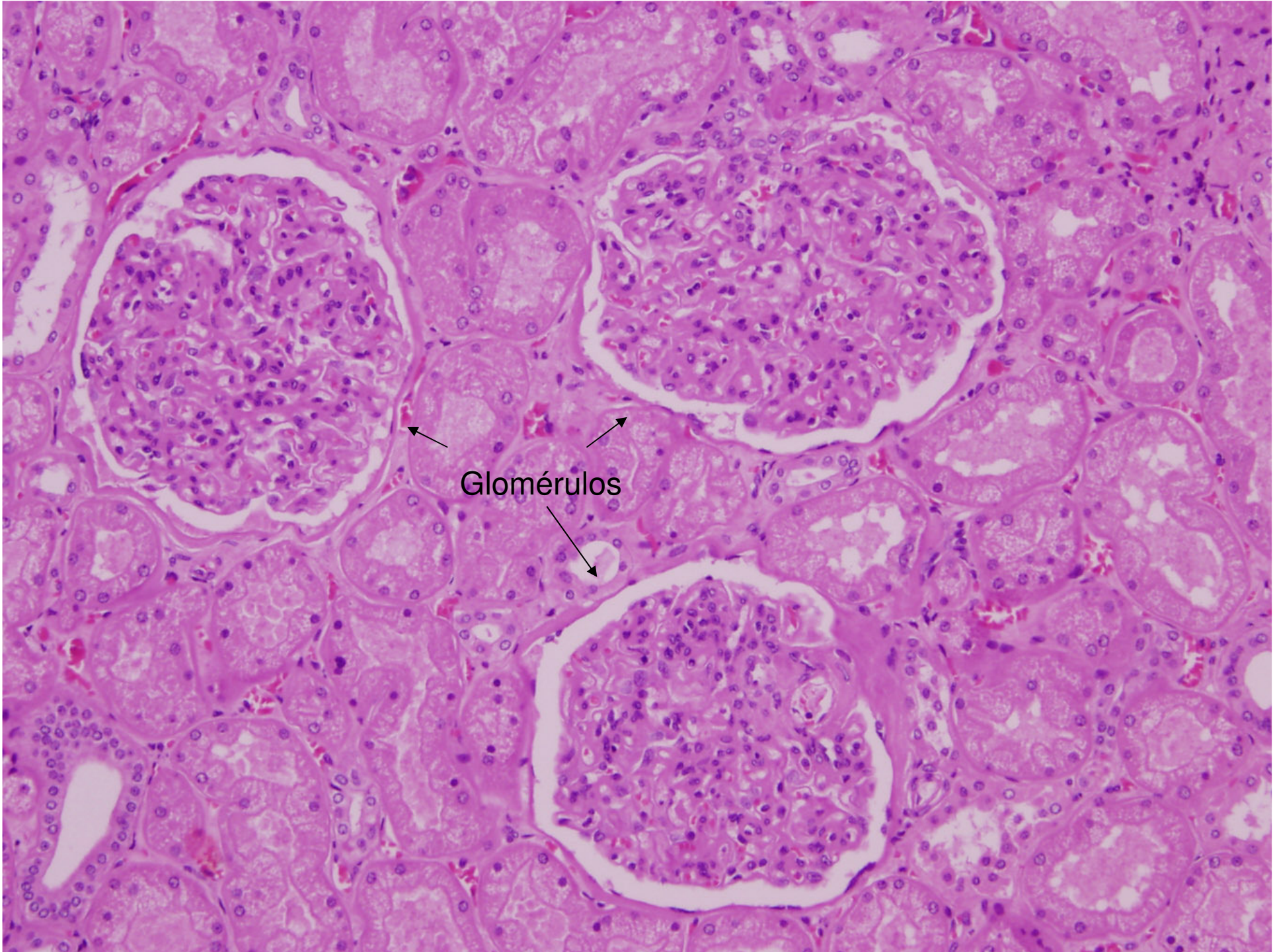
ATLAS DE MICROSCOPIA RIÑÓN



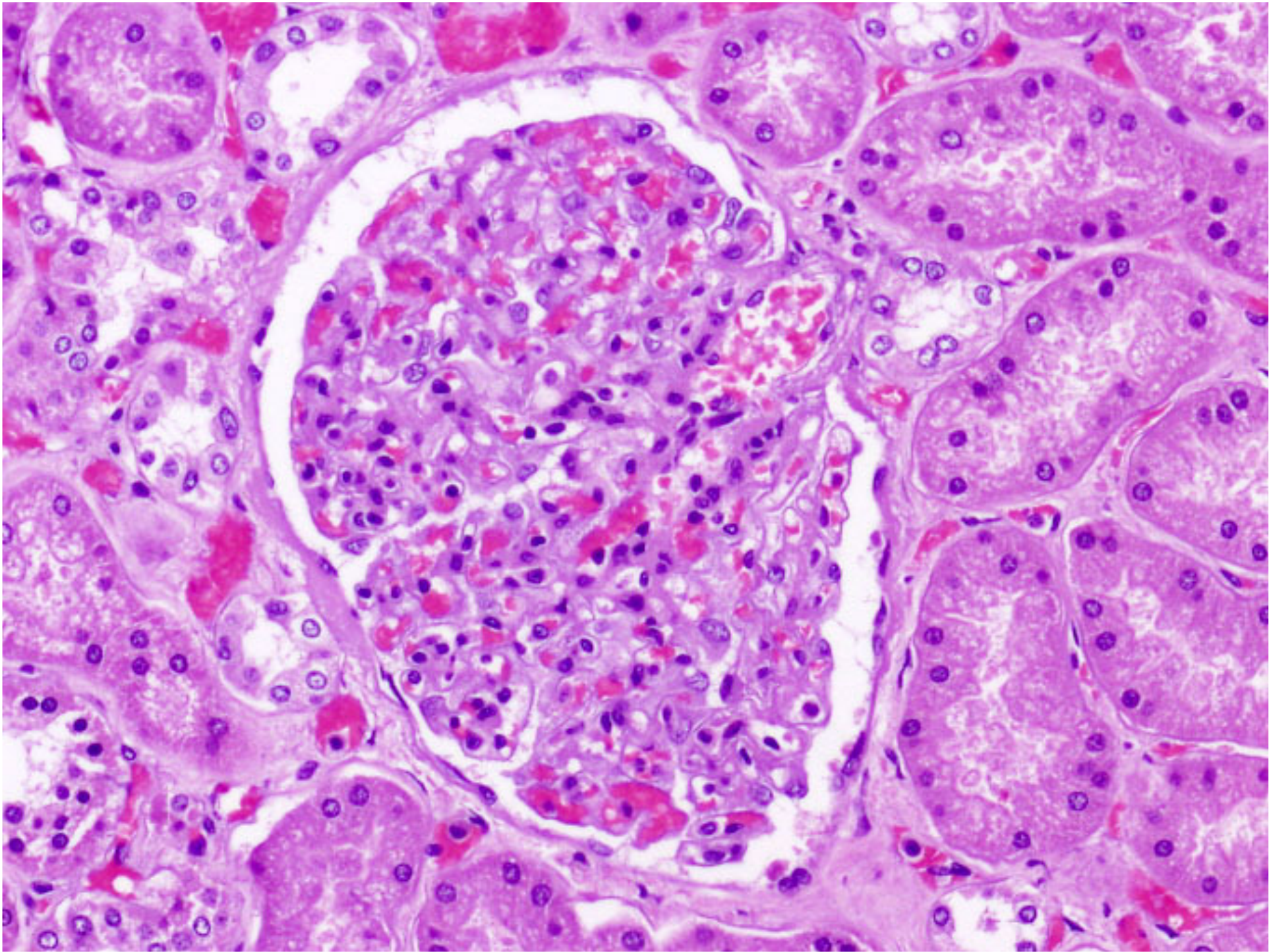
ANATOMIA PATOLOGICA
FACULTAD DE MEDICINA



ANATOMÍA PATOLÓGICA



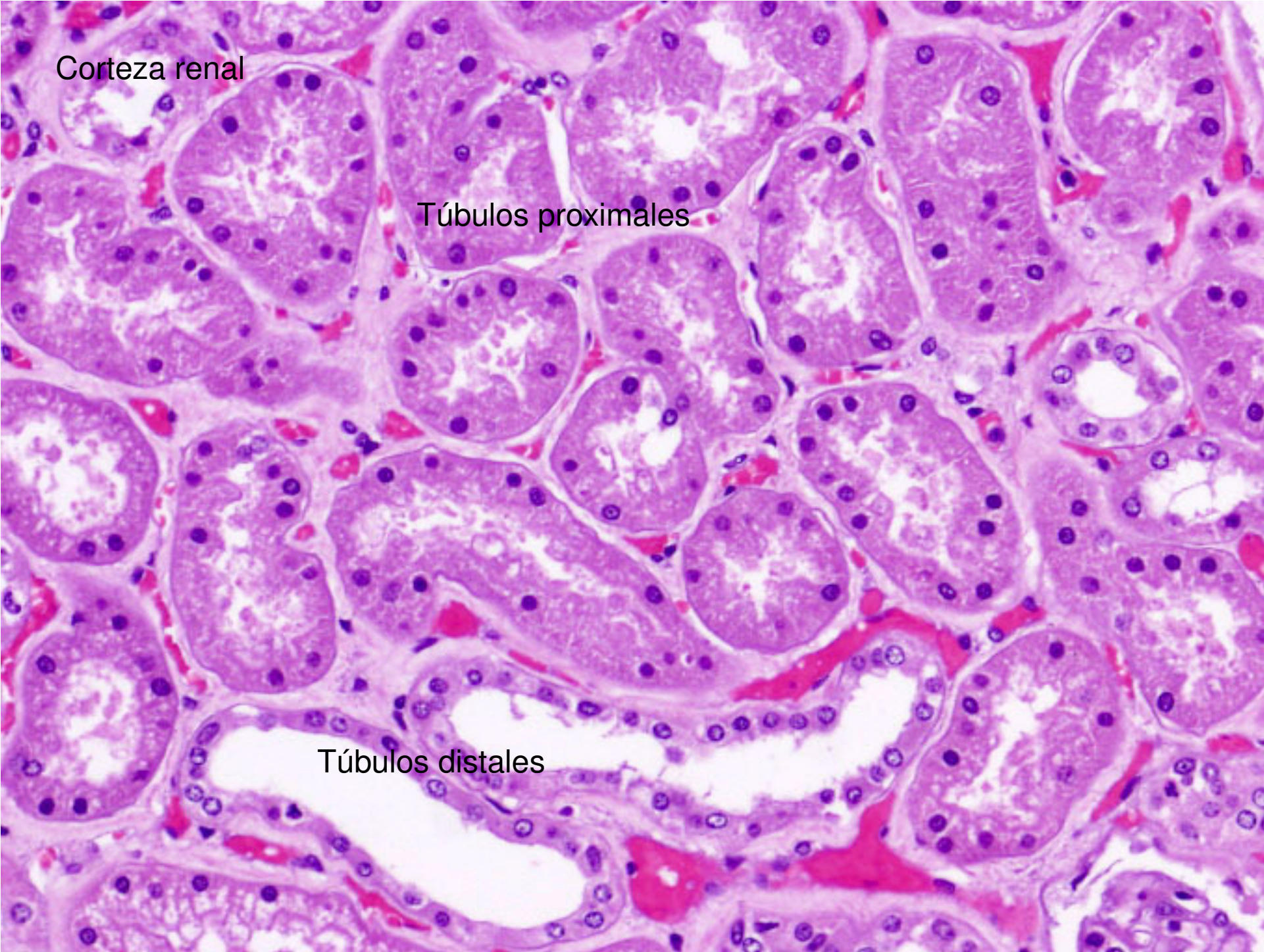
Glomérulos



Corteza renal

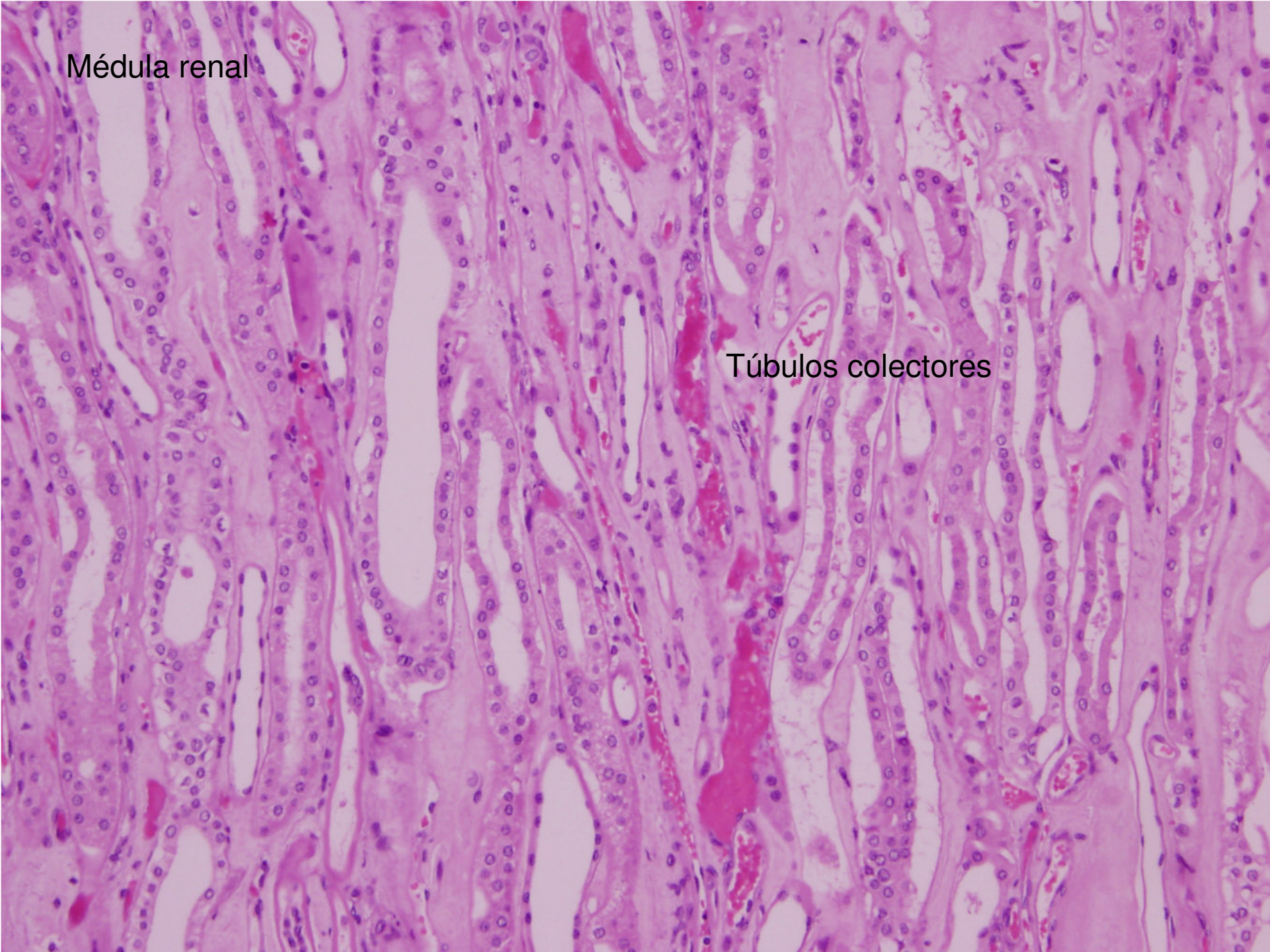
Túbulos proximales

Túbulos distales

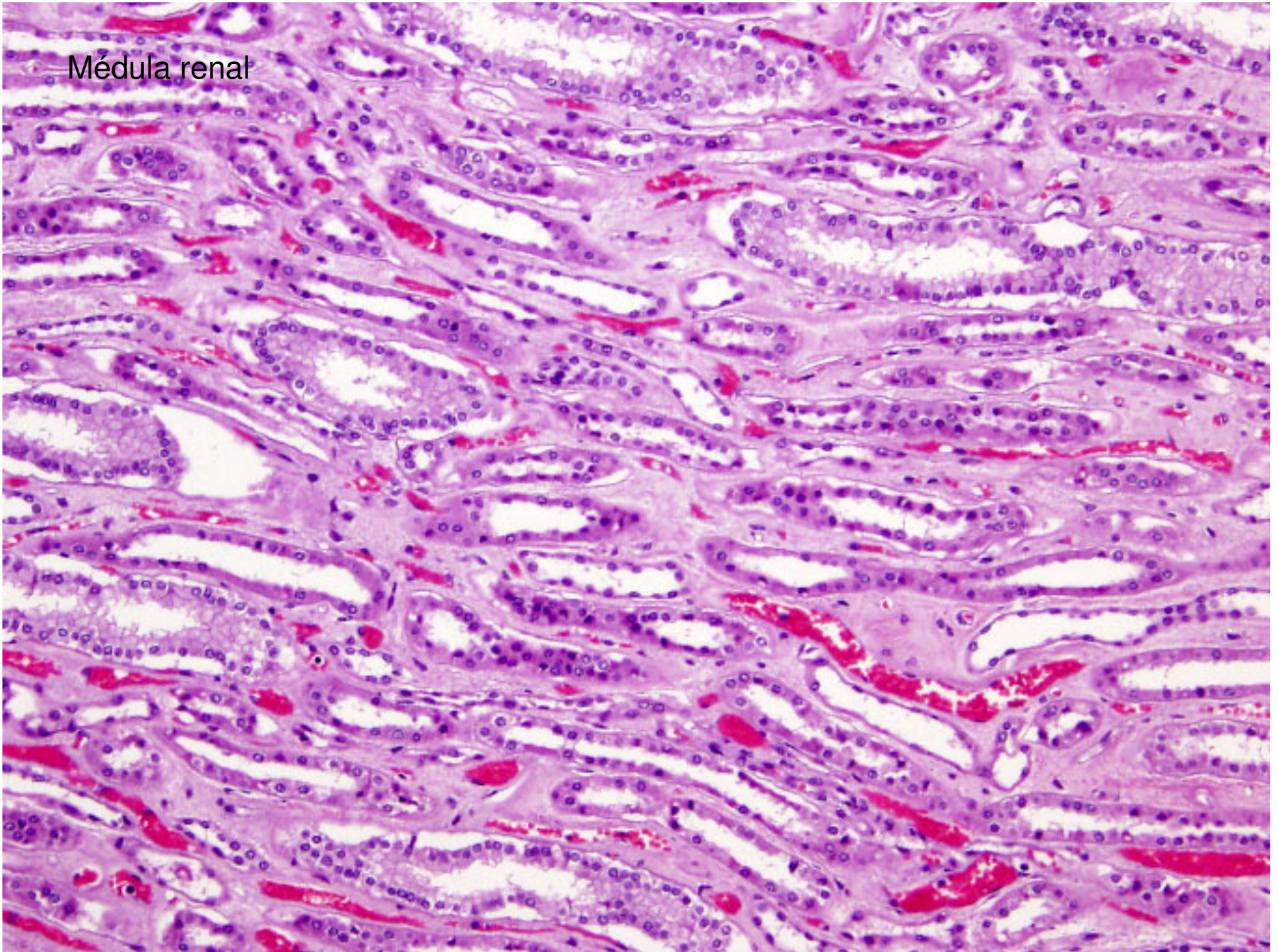


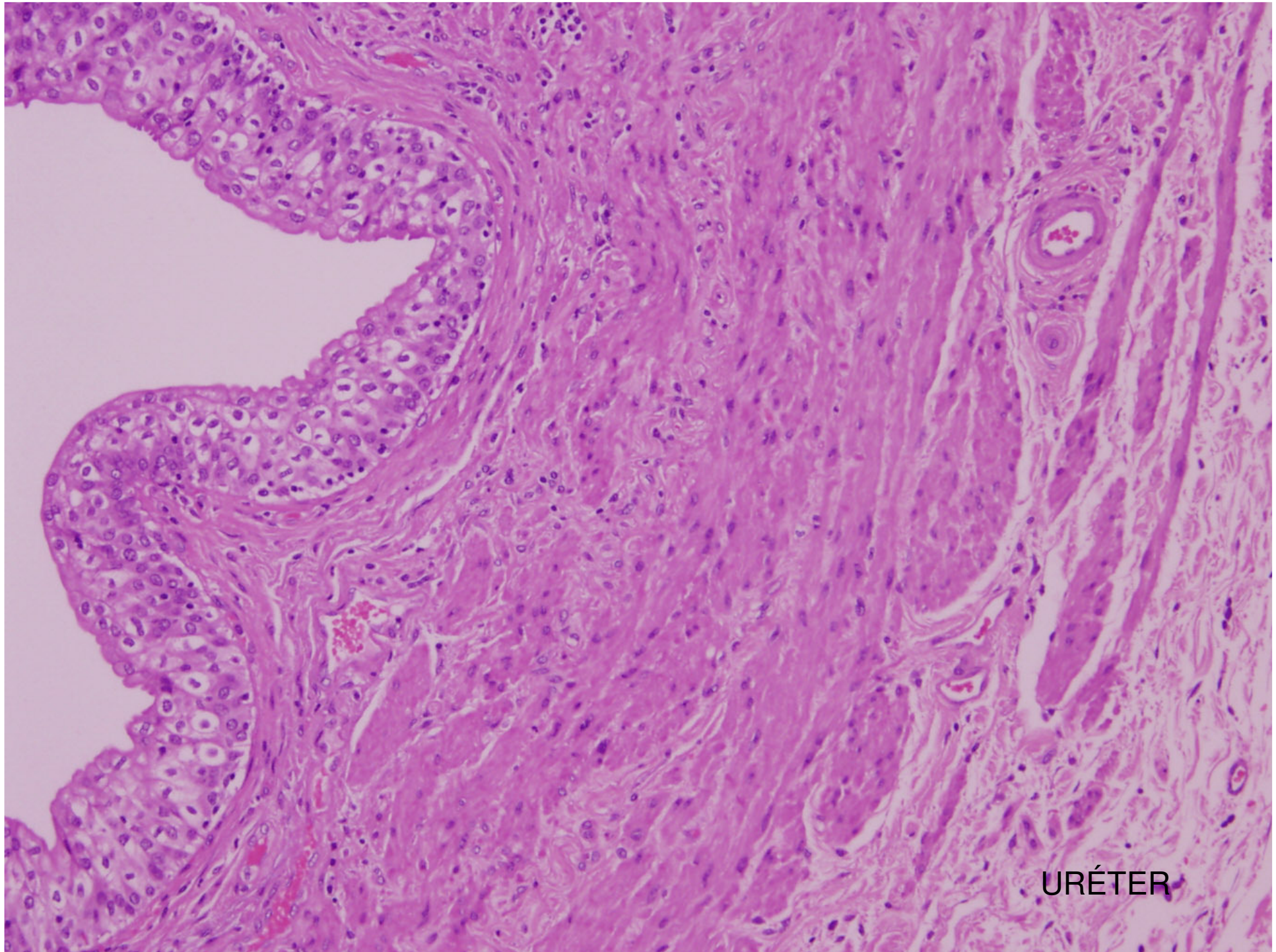
Médula renal

Túbulos colectores



Médula renal



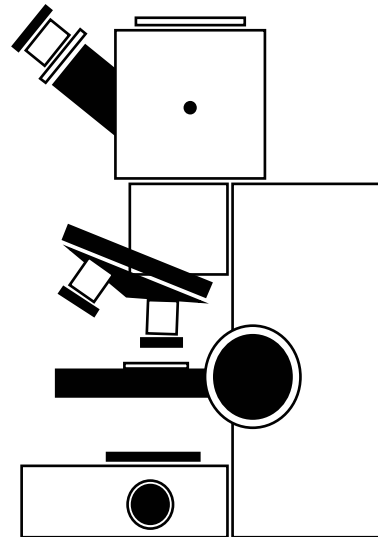


URÉTER

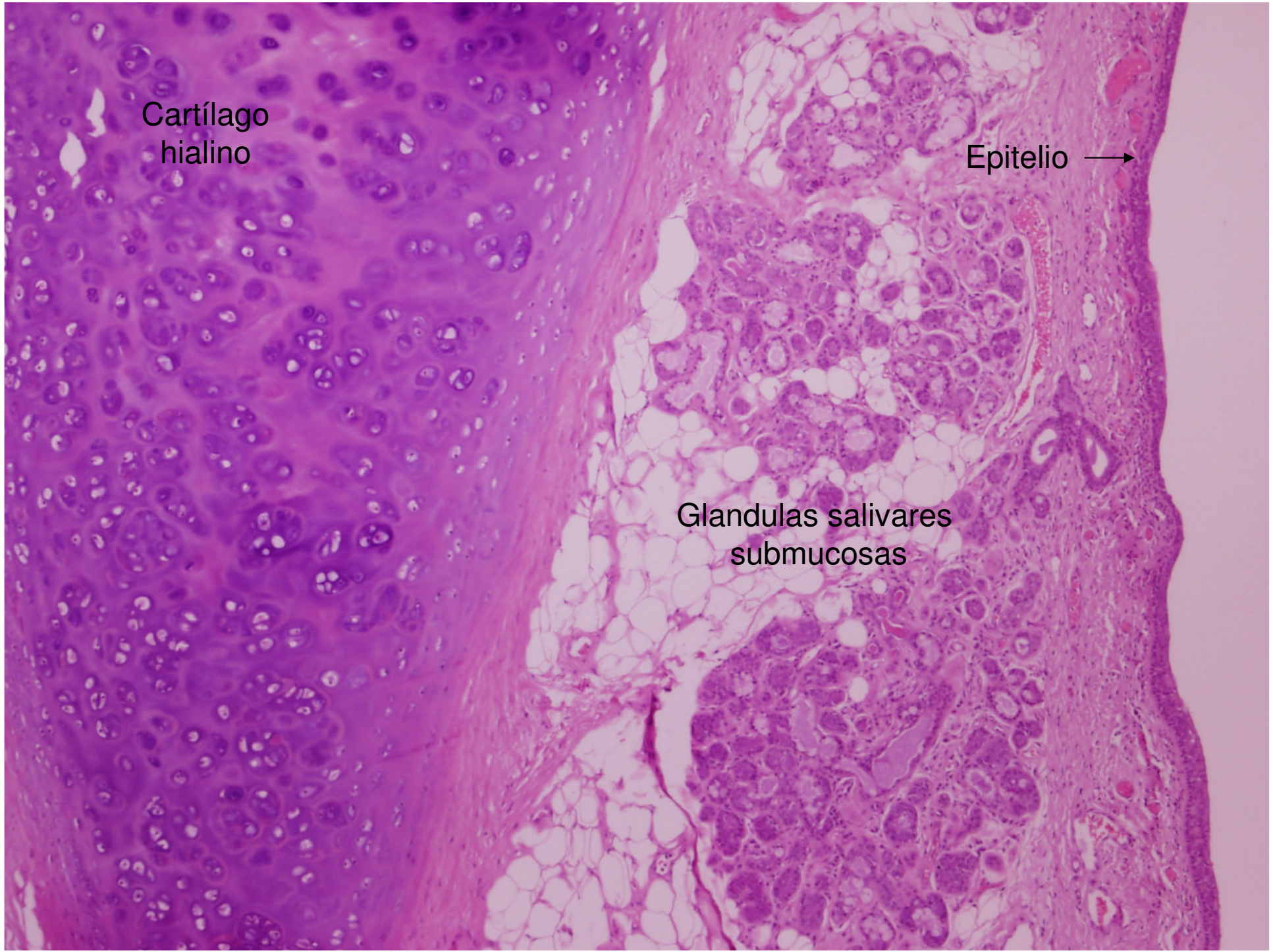
ATLAS DE MICROSCOPIA TRAQUEA



ANATOMIA PATOLOGICA
FACULTAD DE MEDICINA



ANATOMÍA PATOLÓGICA



Cartílago
hialino

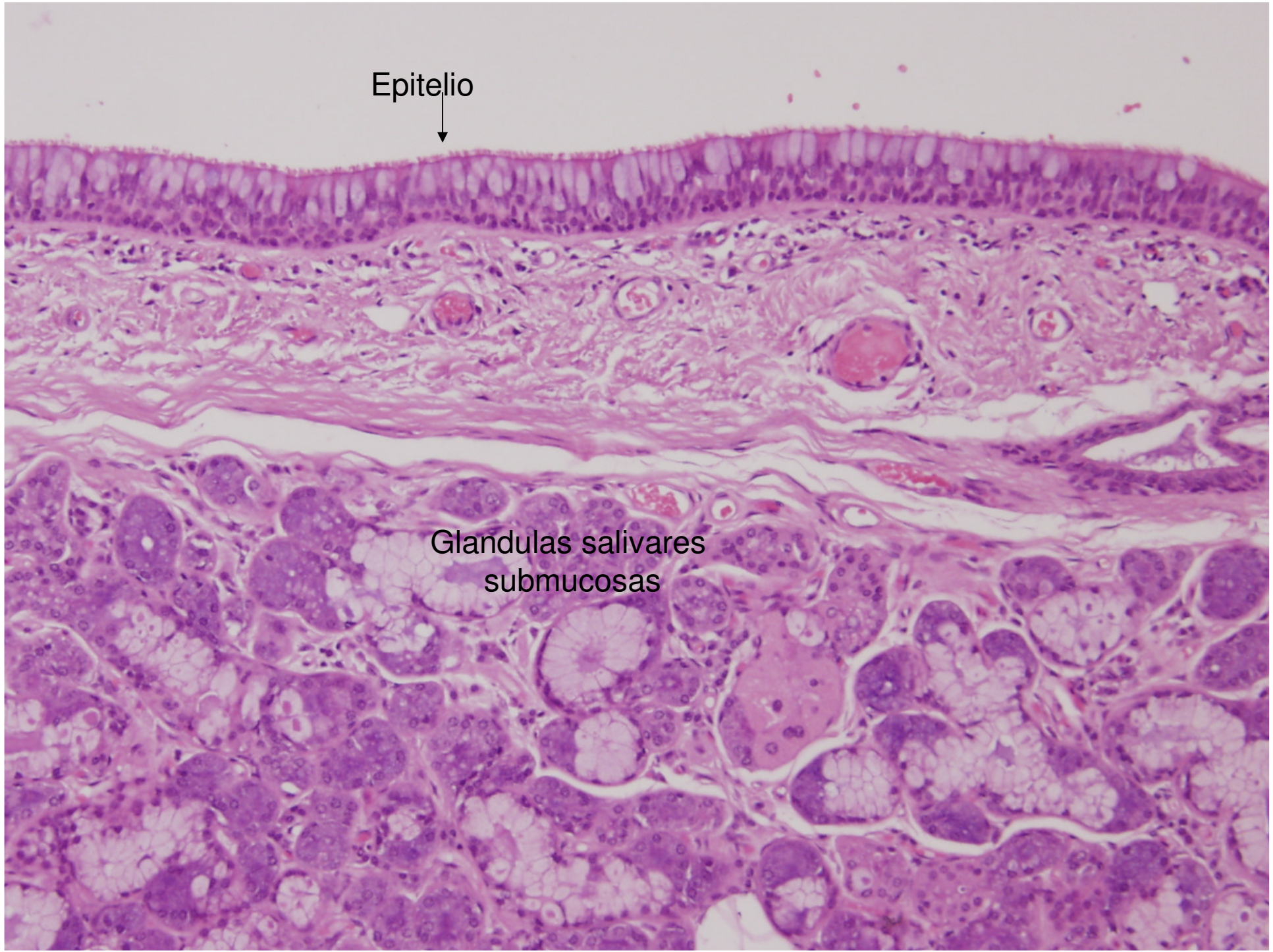
Epitelio →

Glandulas salivares
submucosas

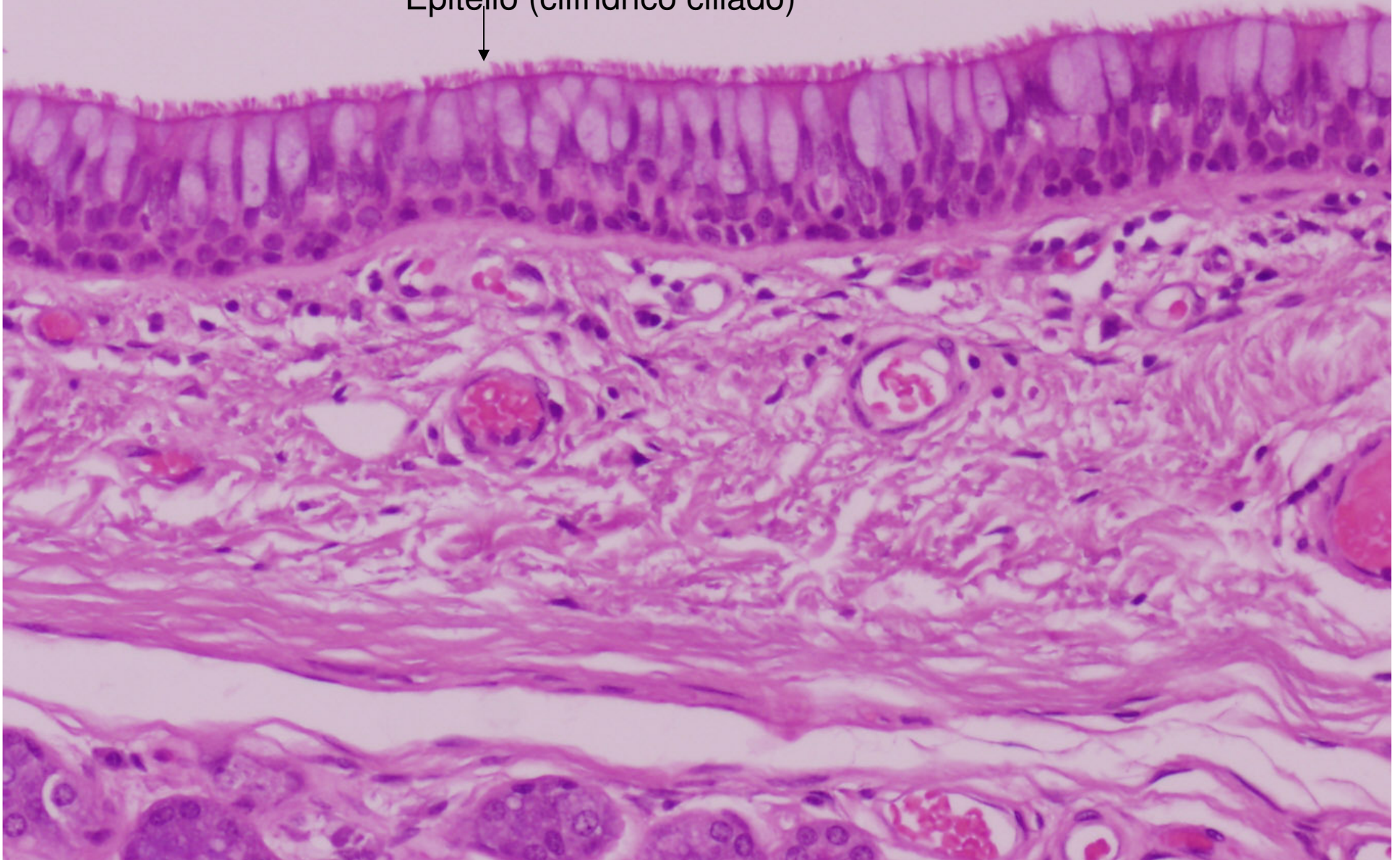
Epitelio



Glandulas salivares
submucosas



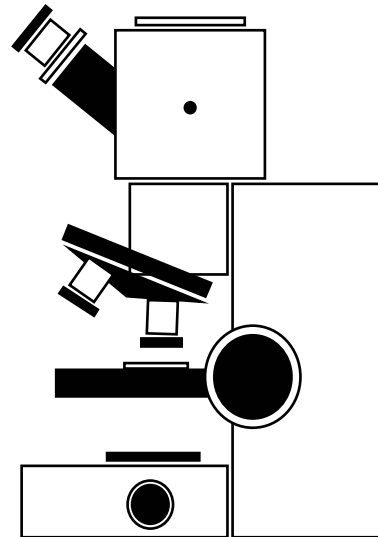
Epitelio (cilíndrico ciliado)



ATLAS DE MICROSCOPIA PULMÓN

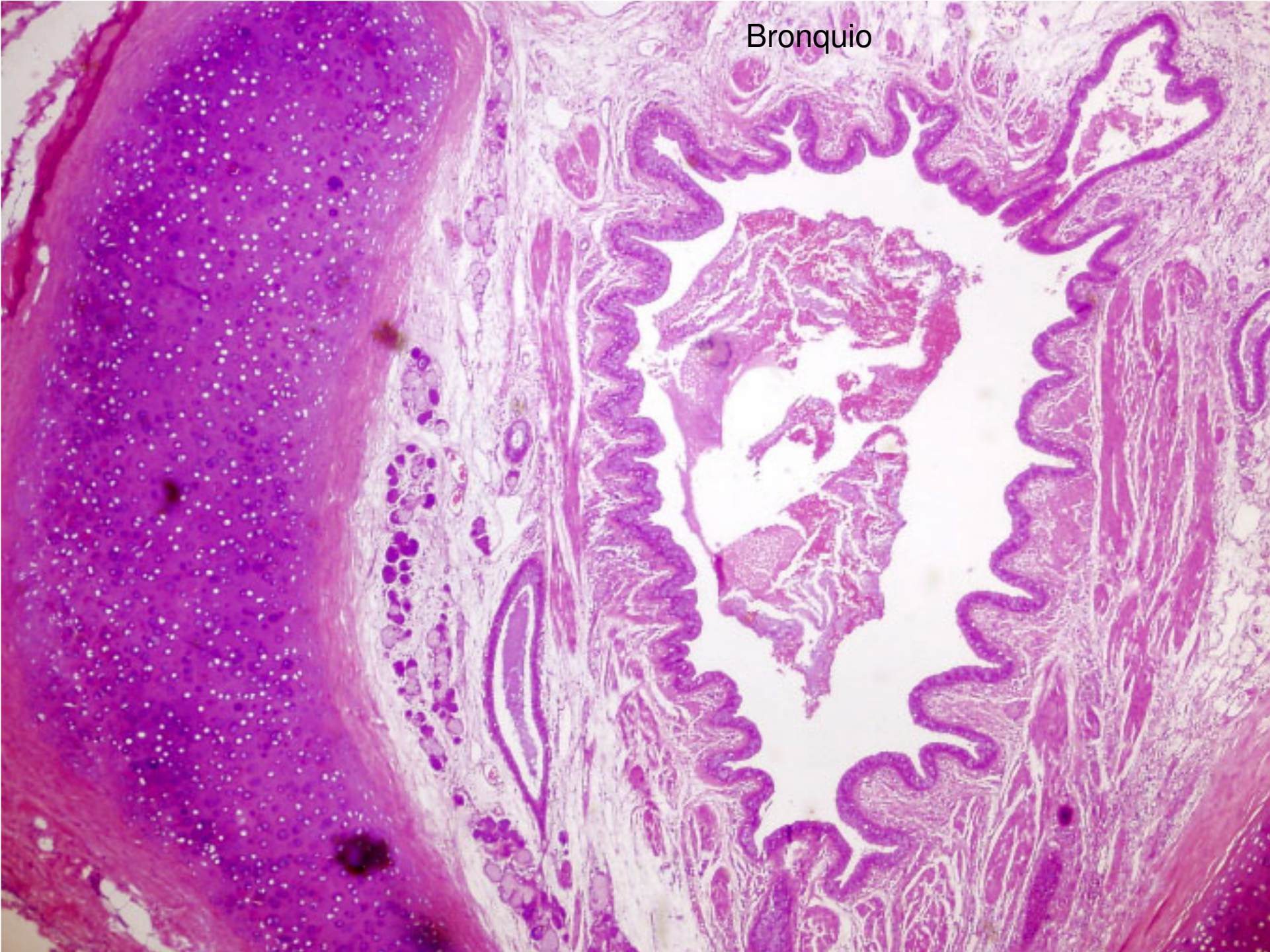


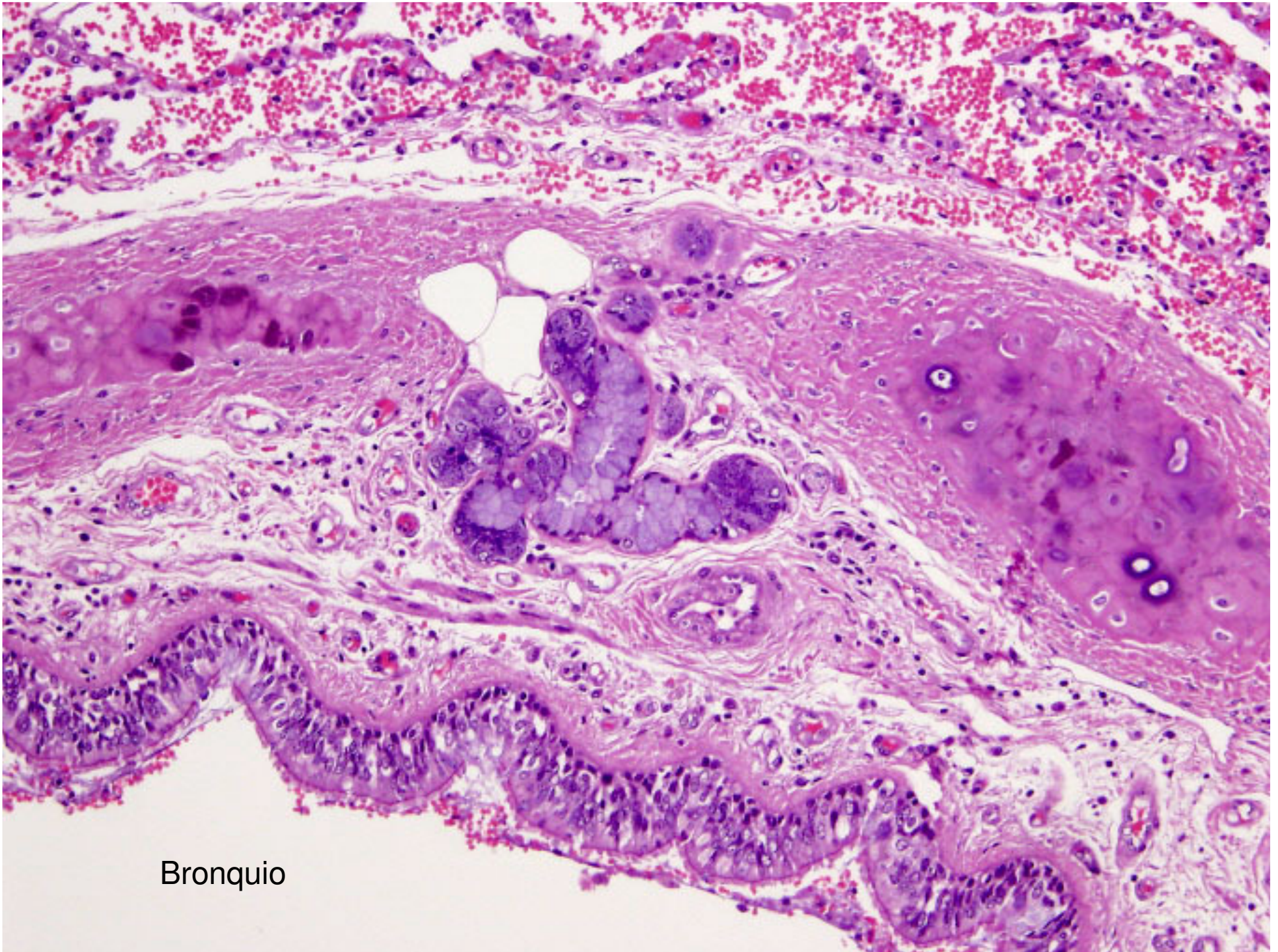
ANATOMIA PATOLÓGICA
FACULTAD DE MEDICINA



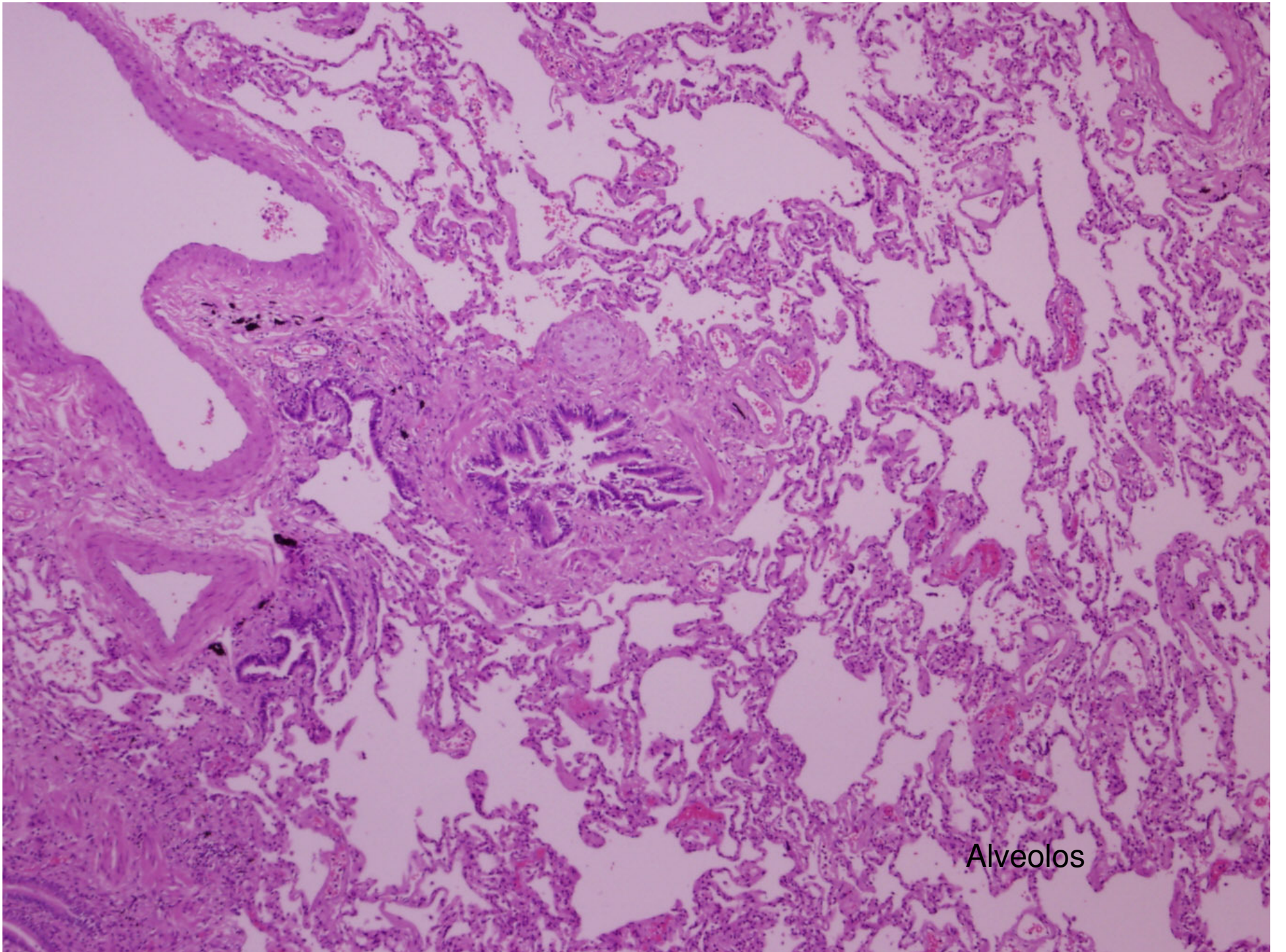
ANATOMÍA PATOLÓGICA

Bronquio

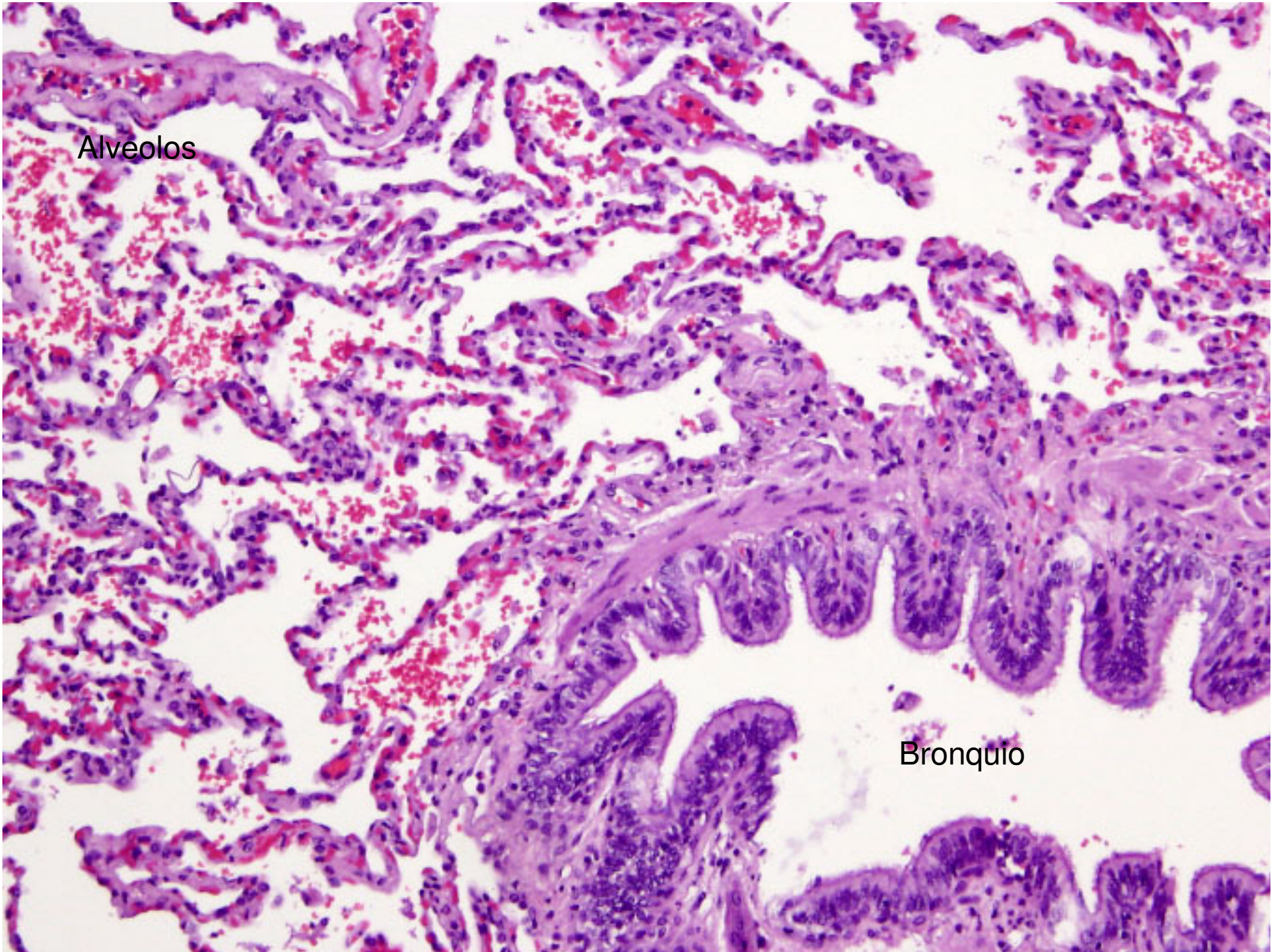




Bronquio



Alveolos



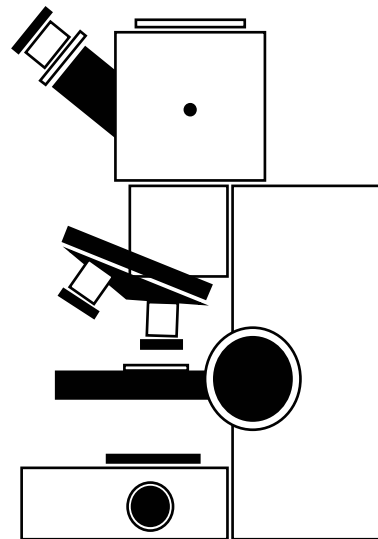
Alveolos

Bronquio

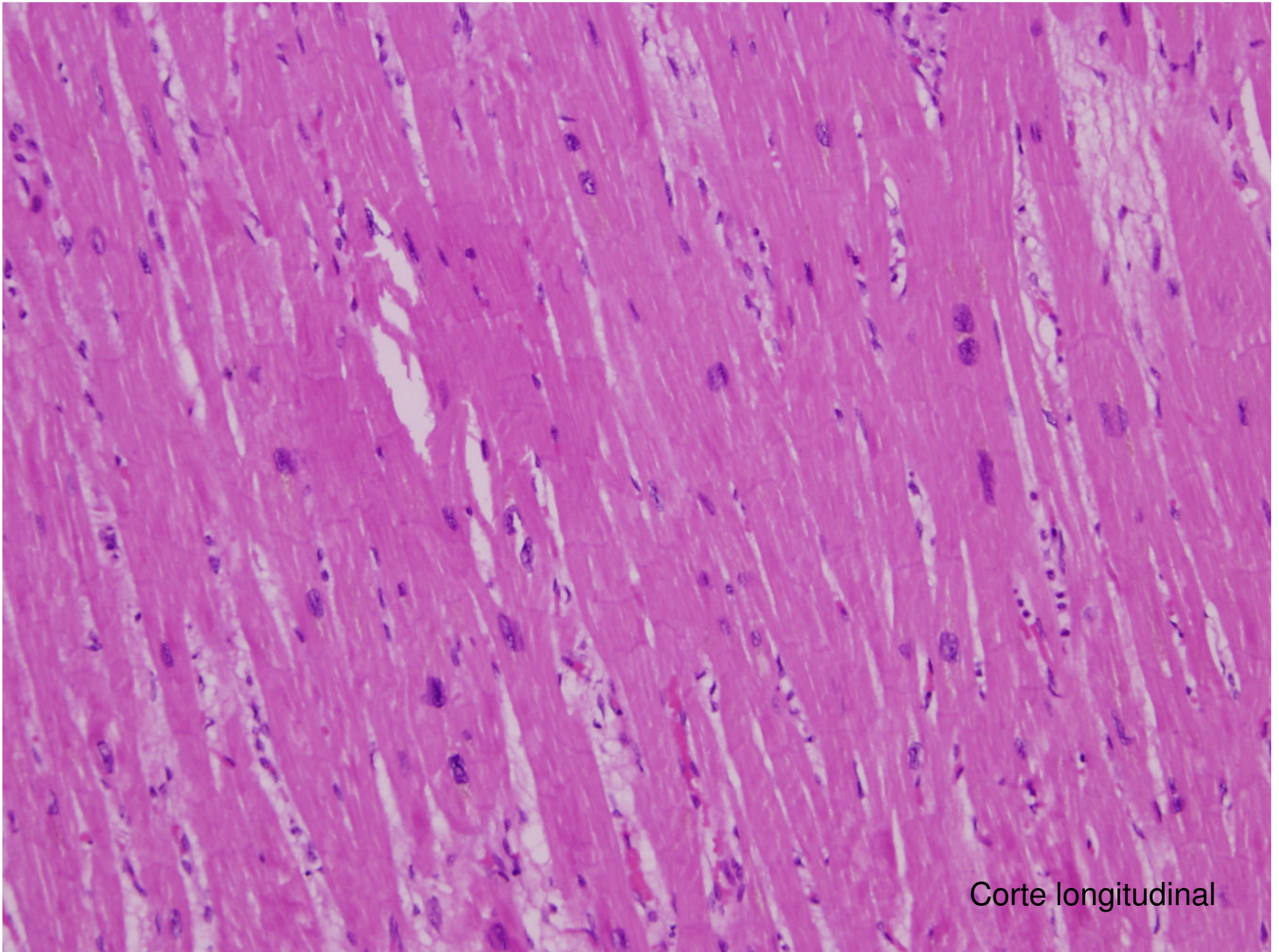
ATLAS DE MICROSCOPIA MÚSCULO CARDÍACO



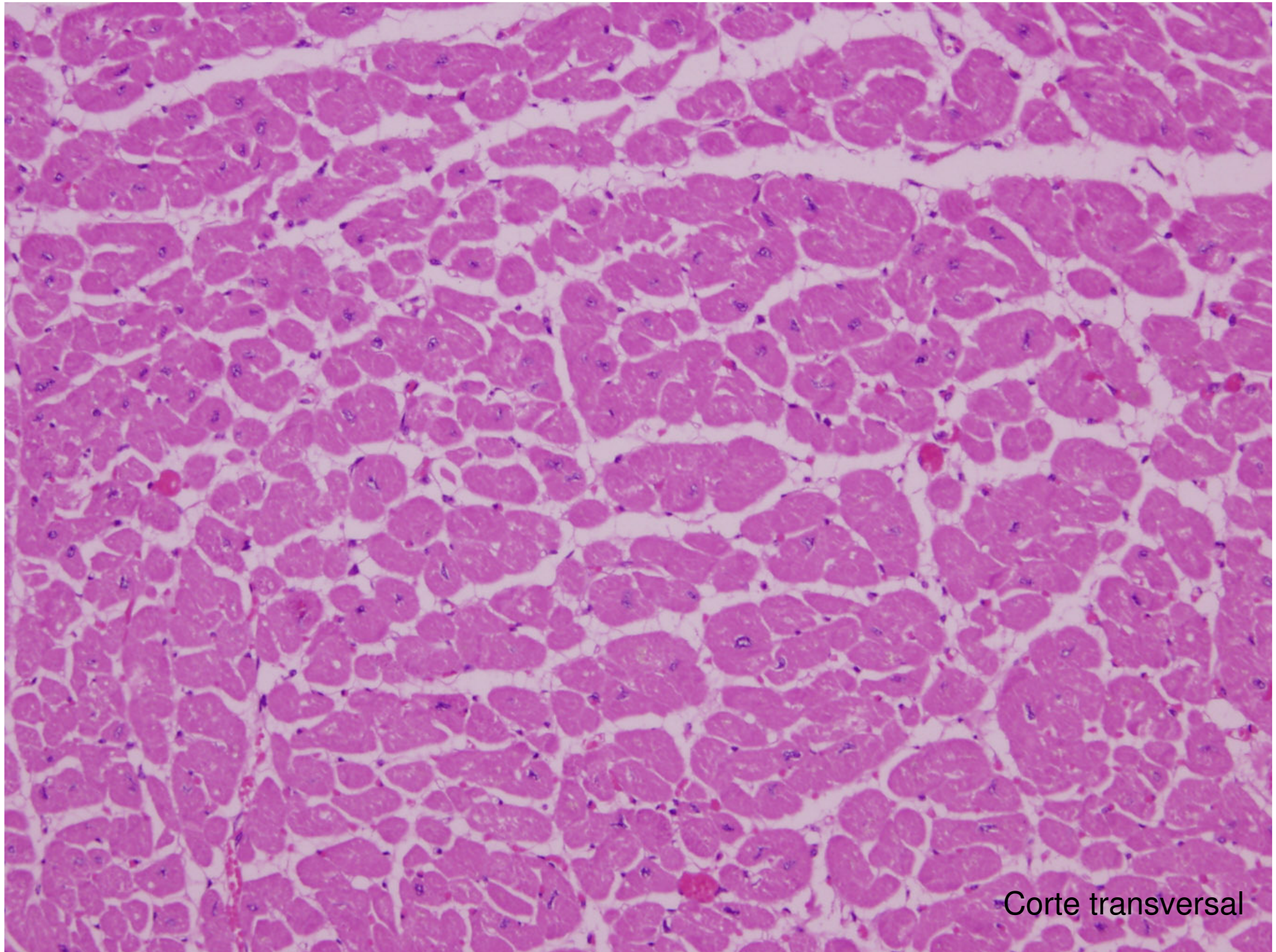
ANATOMIA PATOLÓGICA
FACULTAD DE MEDICINA



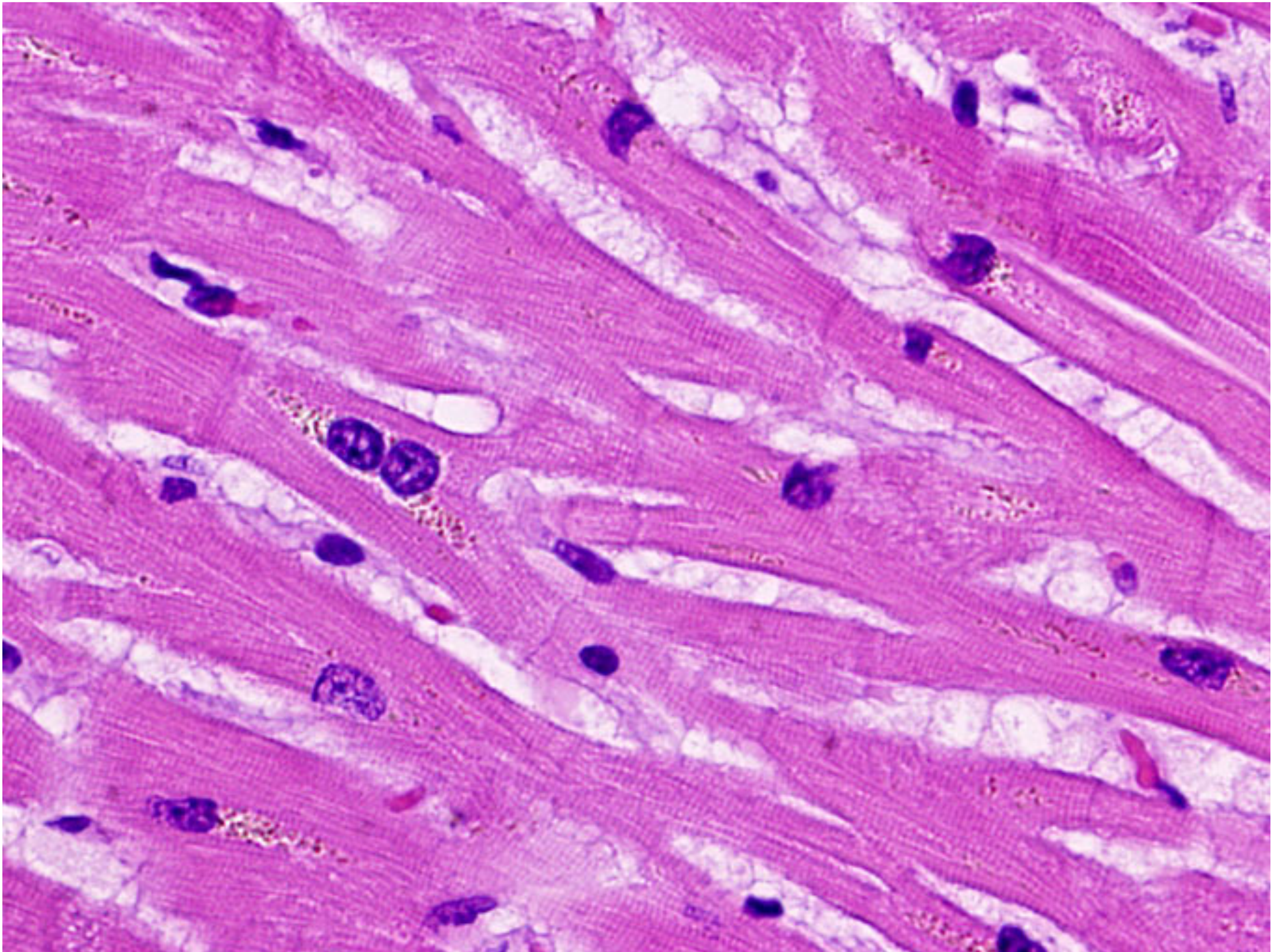
ANATOMÍA PATOLÓGICA



Corte longitudinal



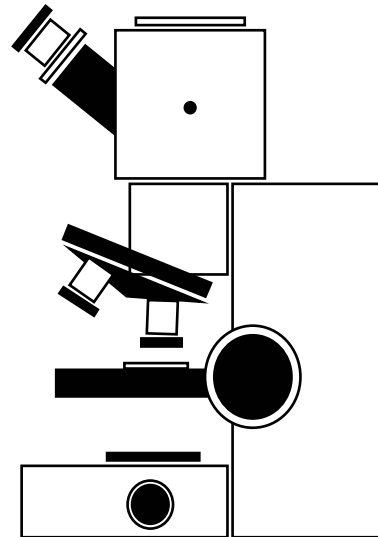
Corte transversal



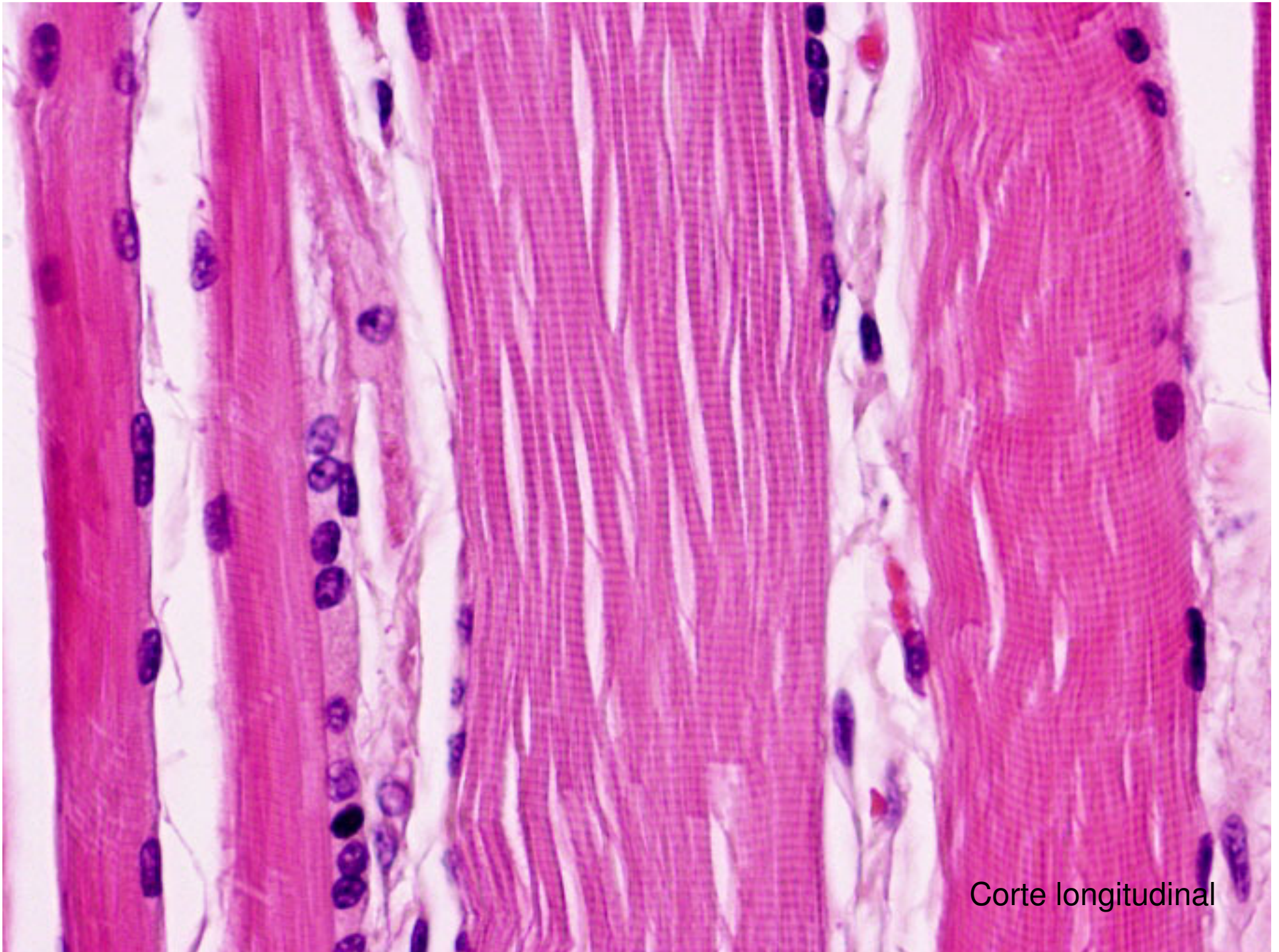
ATLAS DE MICROSCOPIA MÚSCULO ESQUELÉTICO



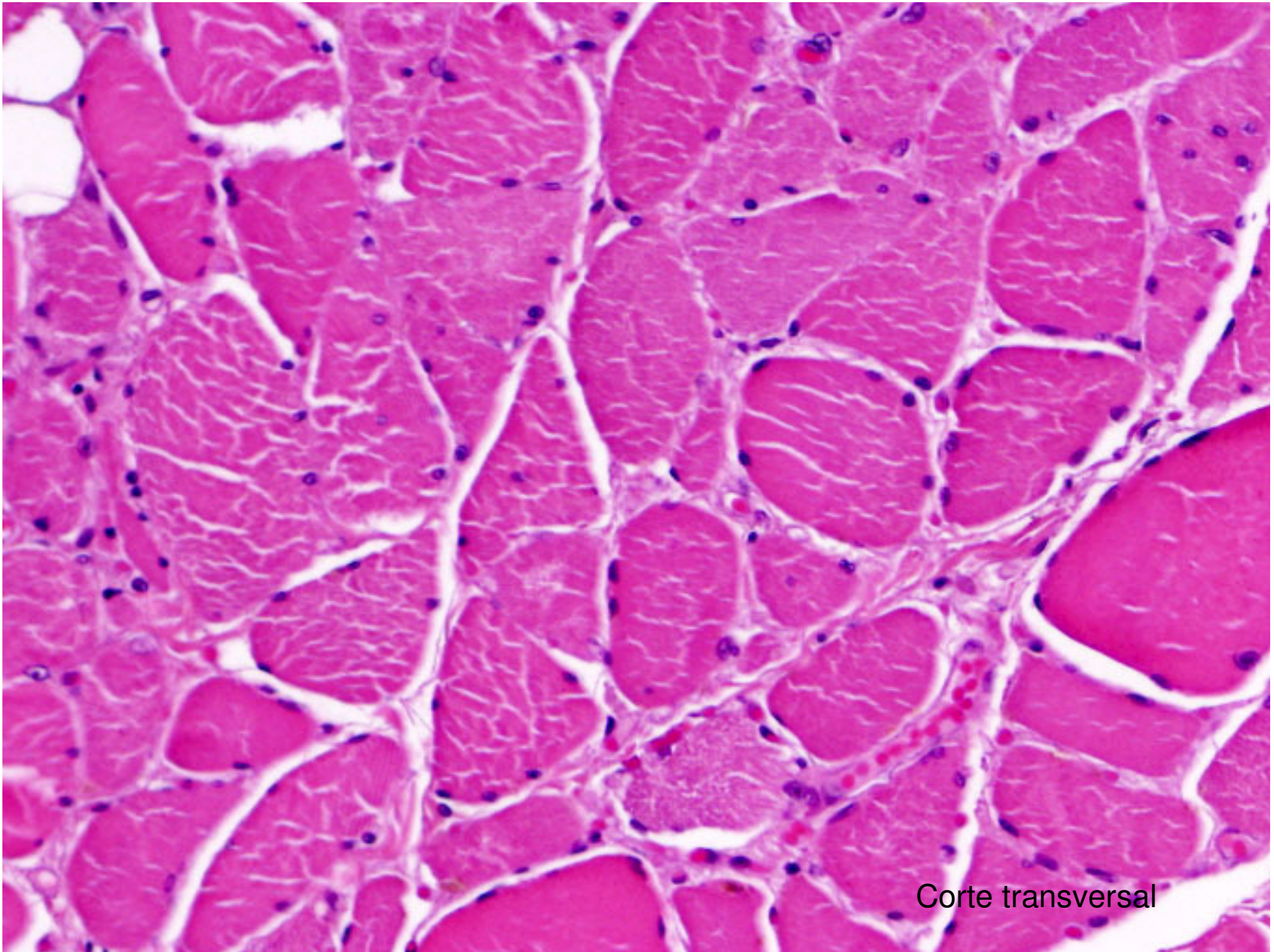
ANATOMIA PATOLÓGICA
FACULTAD DE MEDICINA



ANATOMÍA PATOLÓGICA



Corte longitudinal

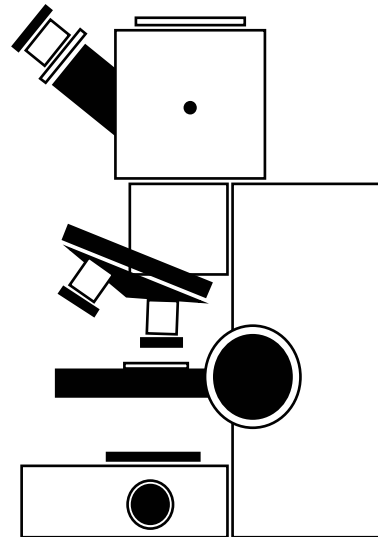


Corte transversal

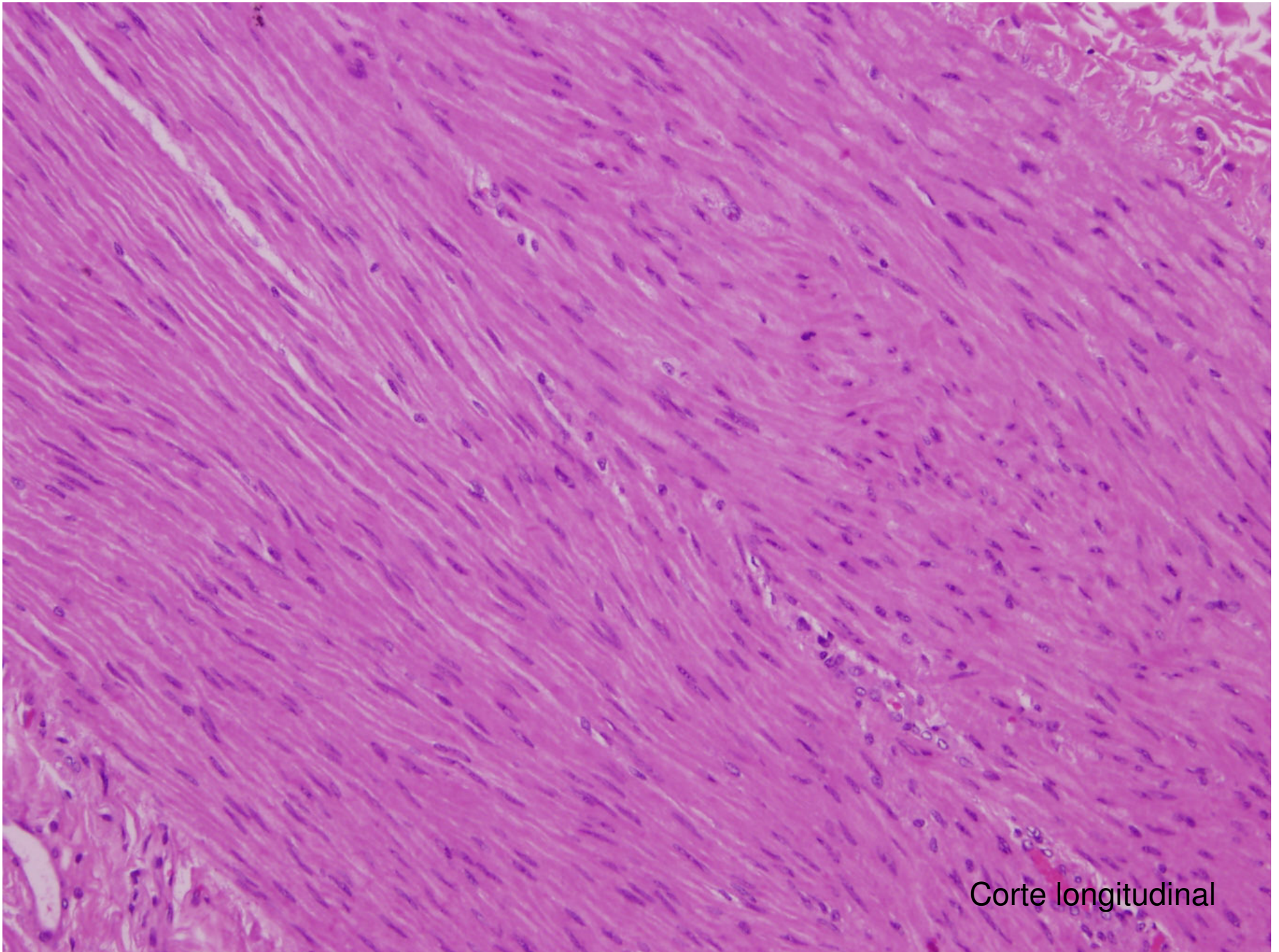
ATLAS DE MICROSCOPIA MÚSCULO LISO



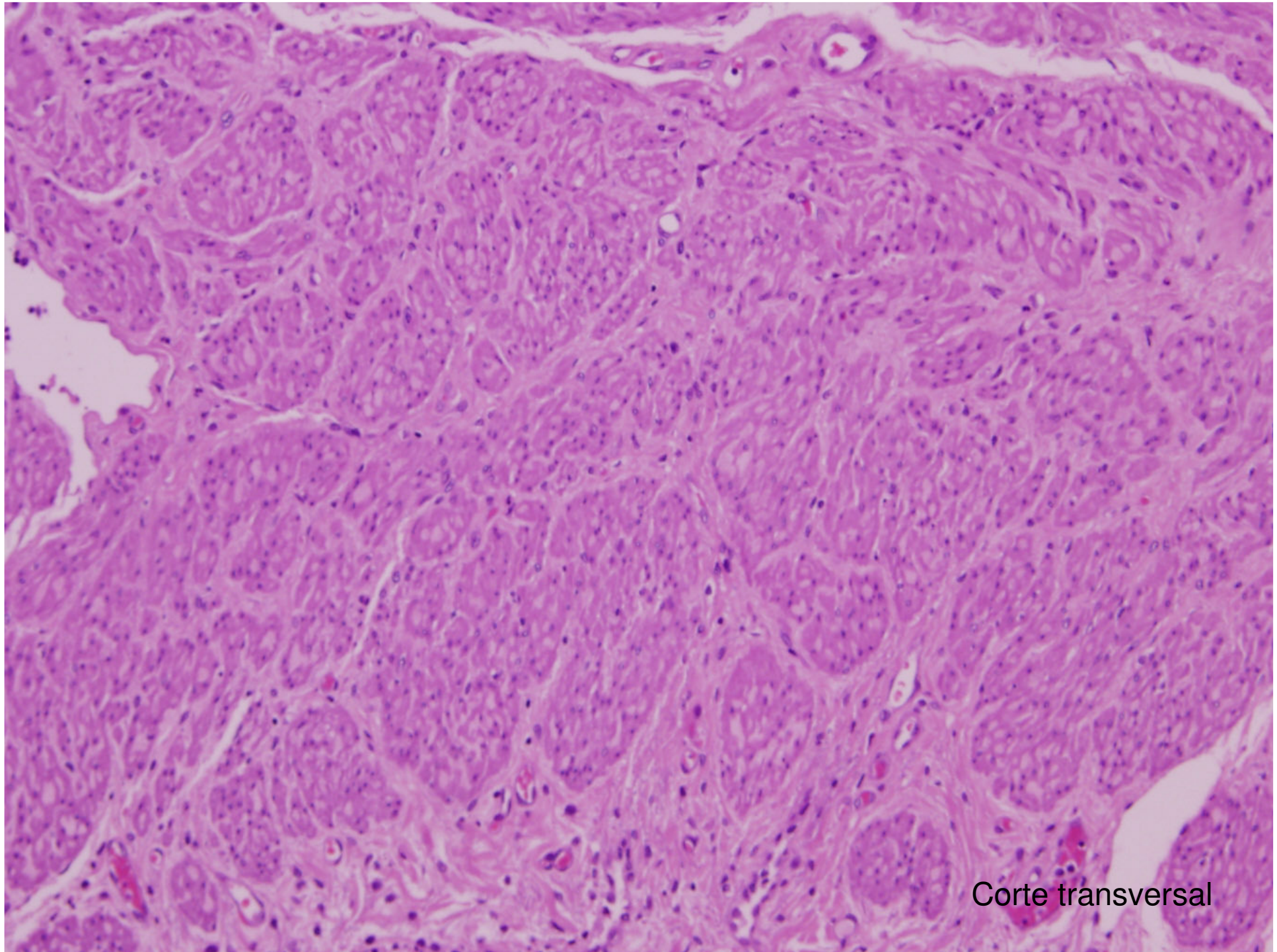
ANATOMIA PATOLÓGICA
FACULTAD DE MEDICINA



ANATOMÍA PATOLÓGICA



Corte longitudinal

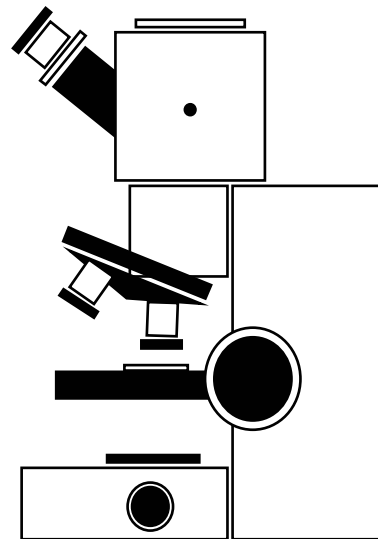


Corte transversal

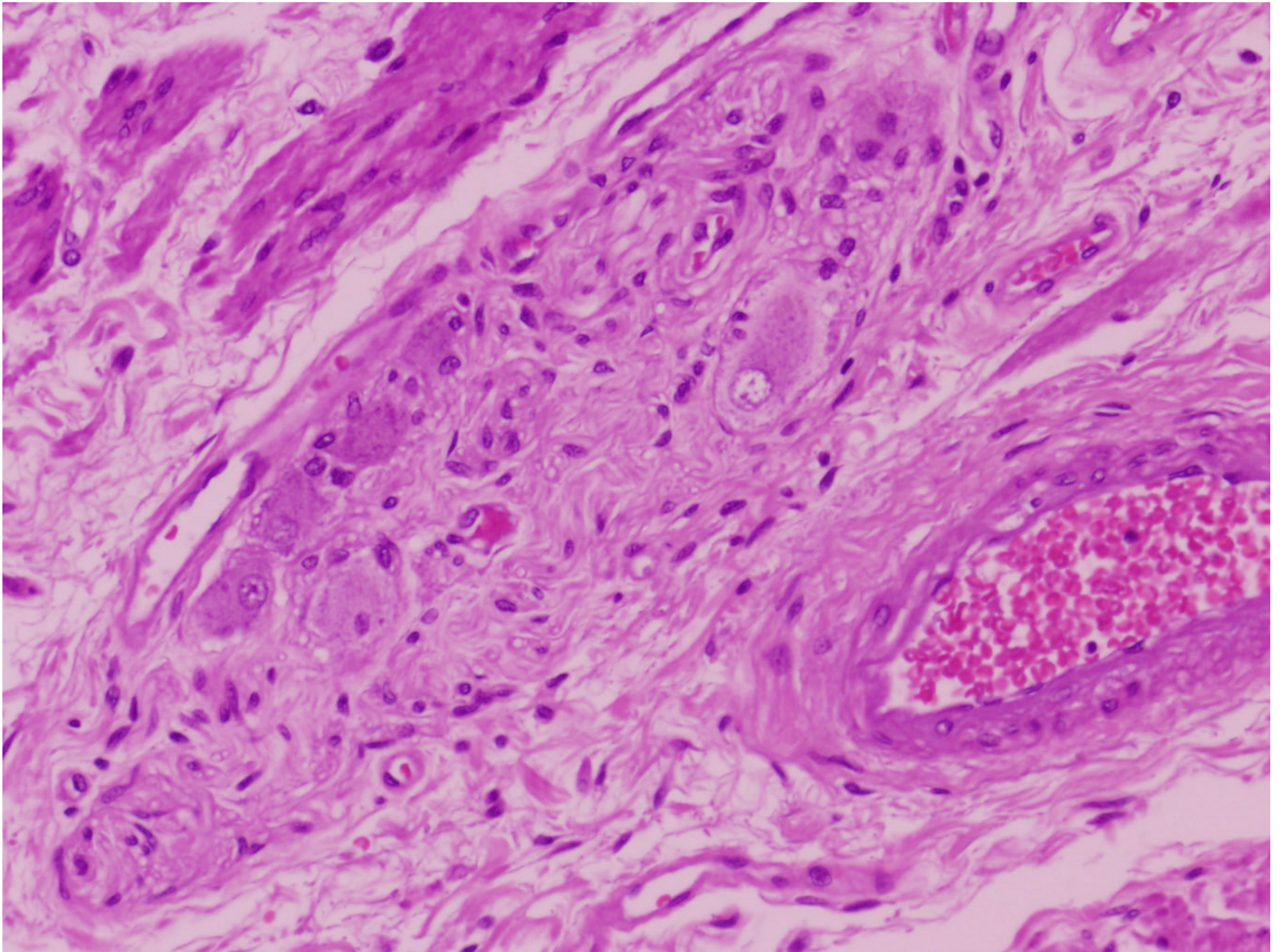
ATLAS DE MICROSCOPIA PLEXO NERVIOSO



ANATOMIA PATOLÓGICA
FACULTAD DE MEDICINA



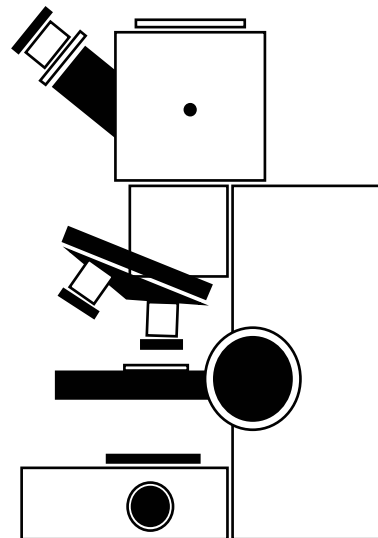
ANATOMÍA PATOLÓGICA



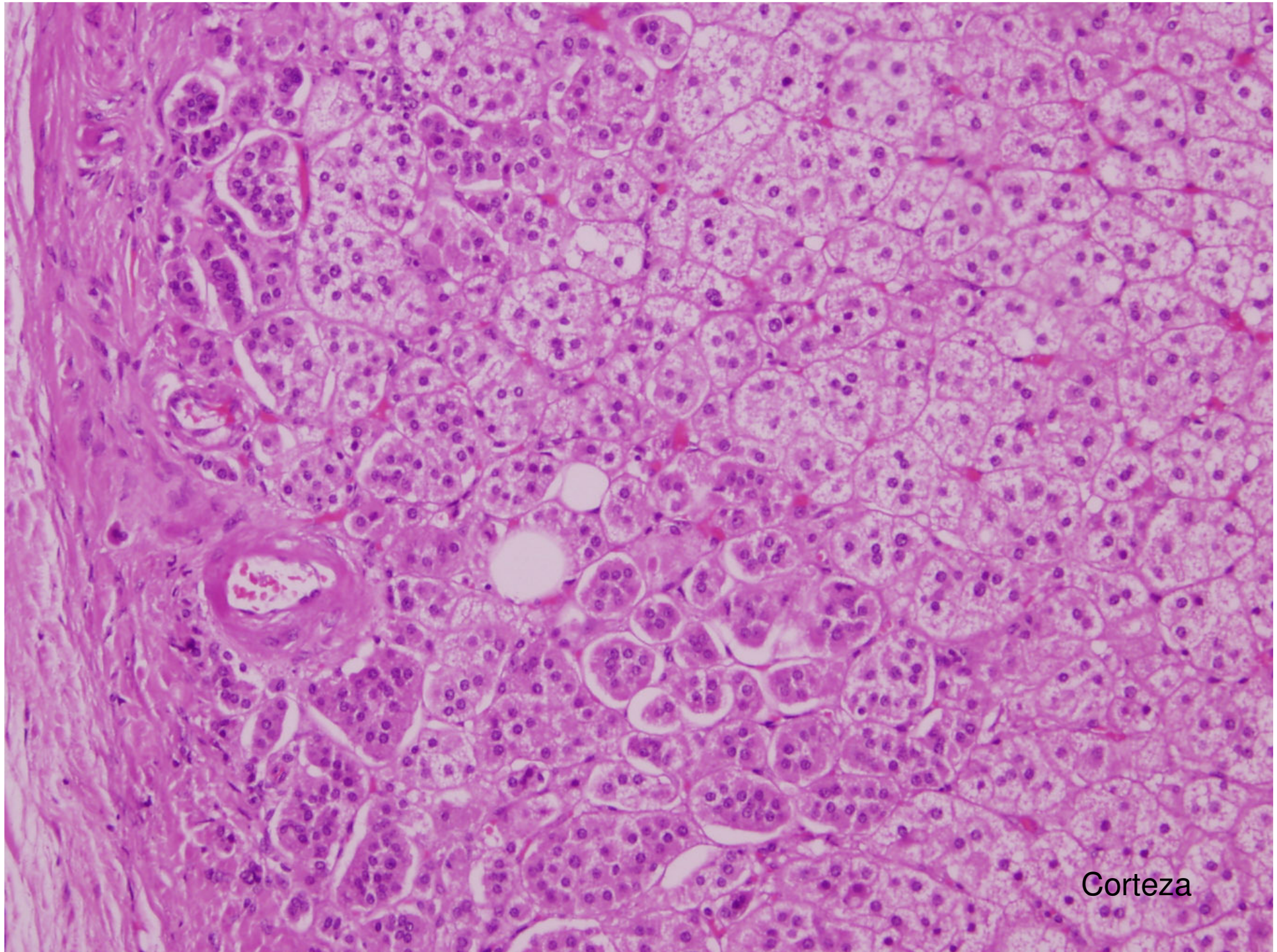
ATLAS DE MICROSCOPIA SUPRARRENAL



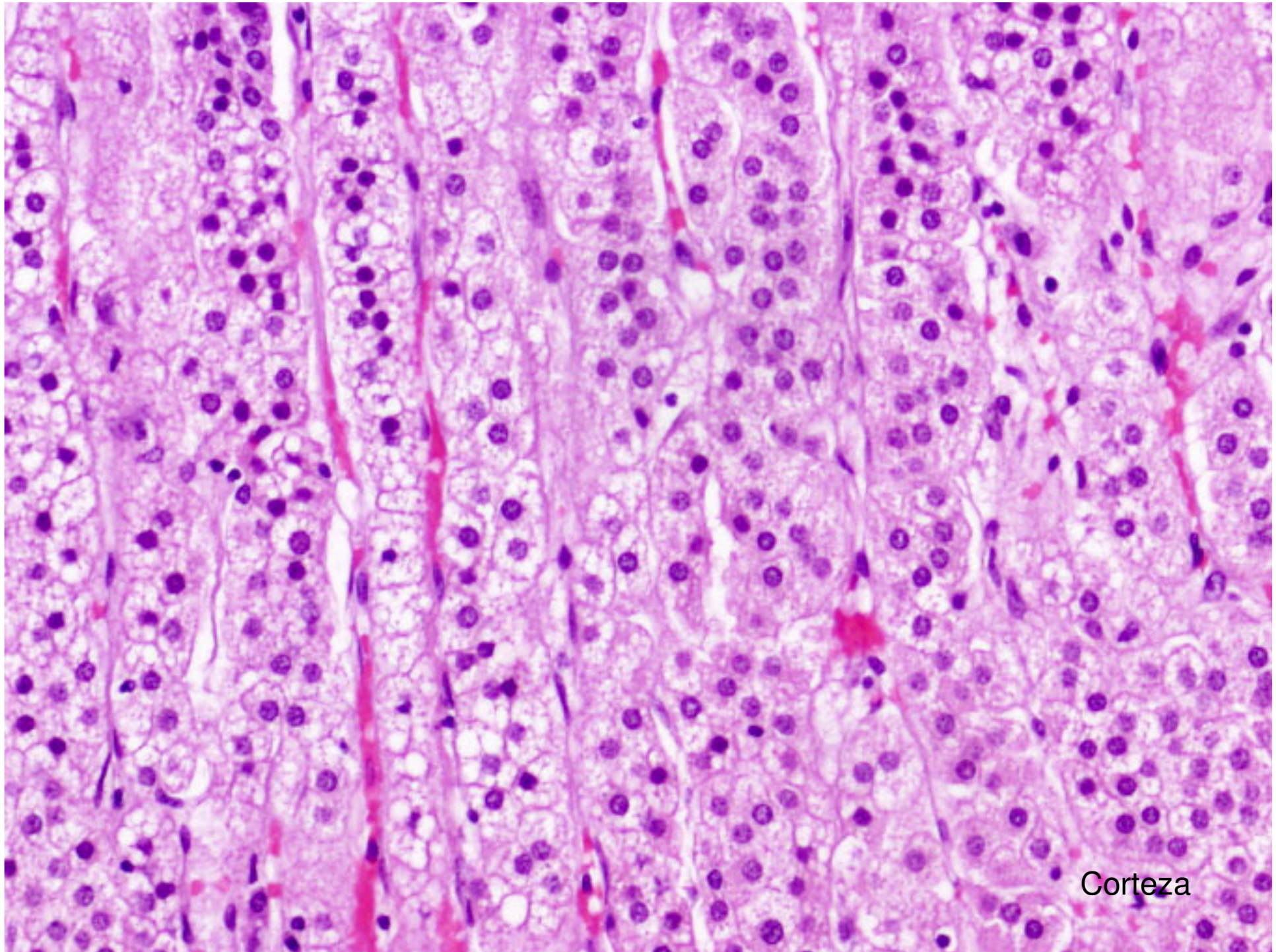
ANATOMIA PATOLOGICA
FACULTAD DE MEDICINA



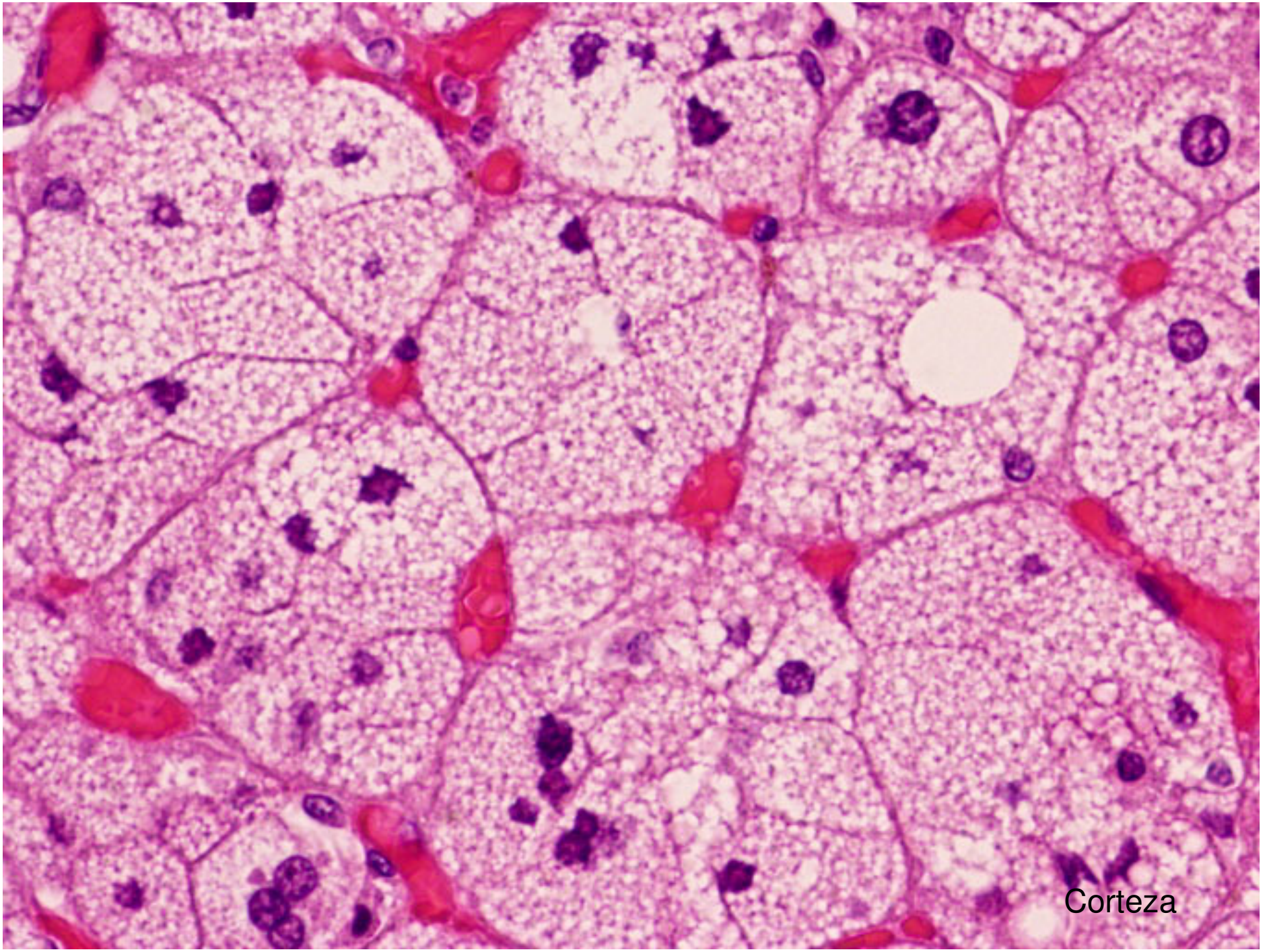
ANATOMÍA PATOLÓGICA



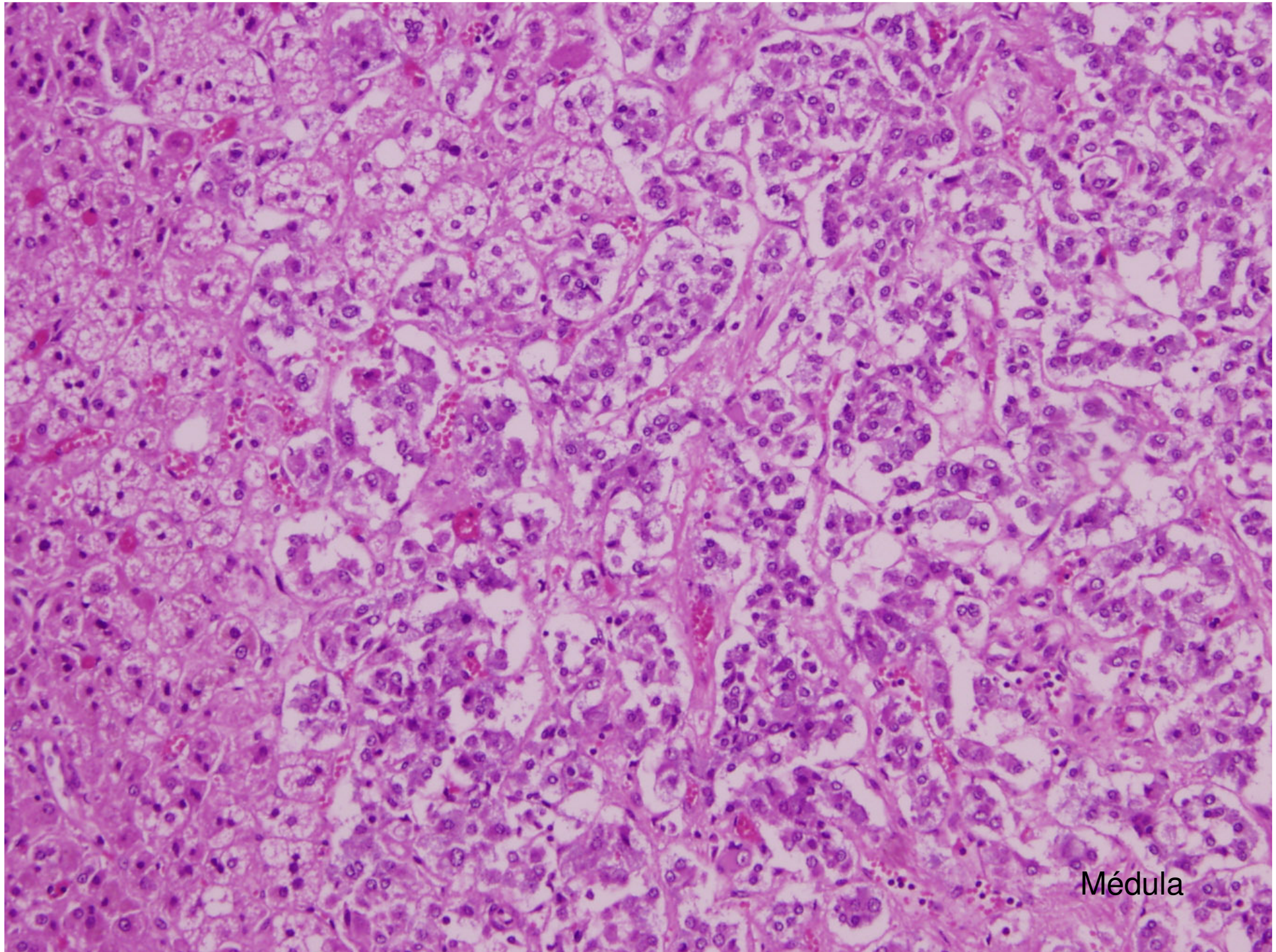
Corteza



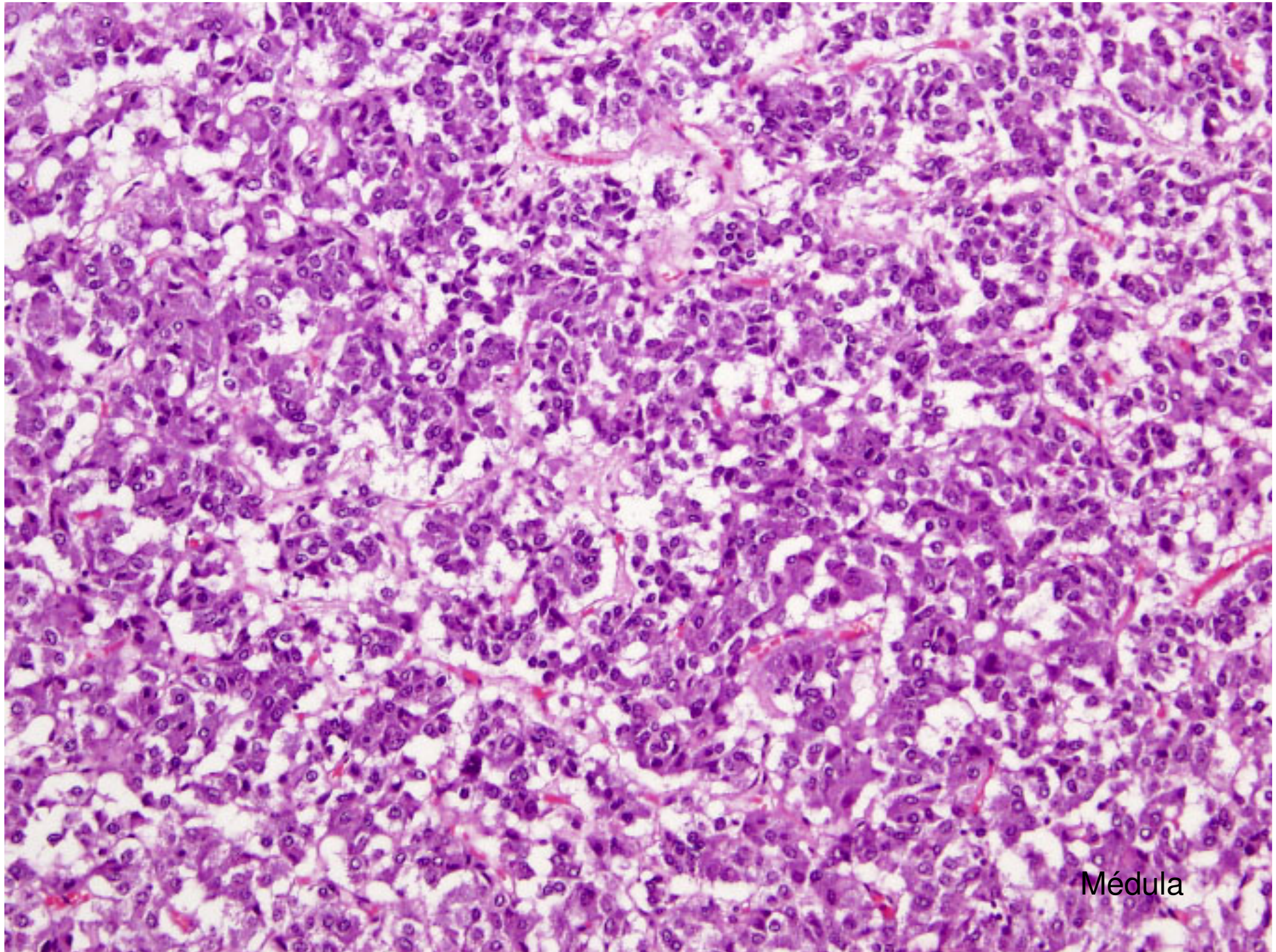
Corteza



Corteza



Médula

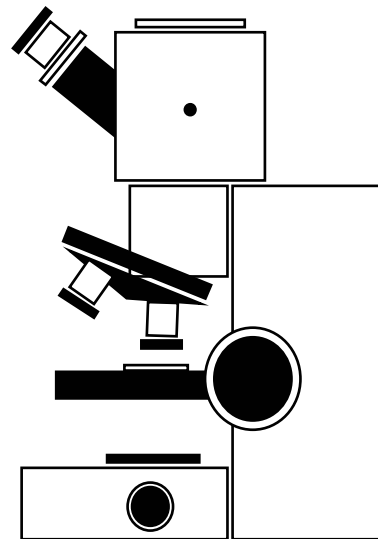


Médula

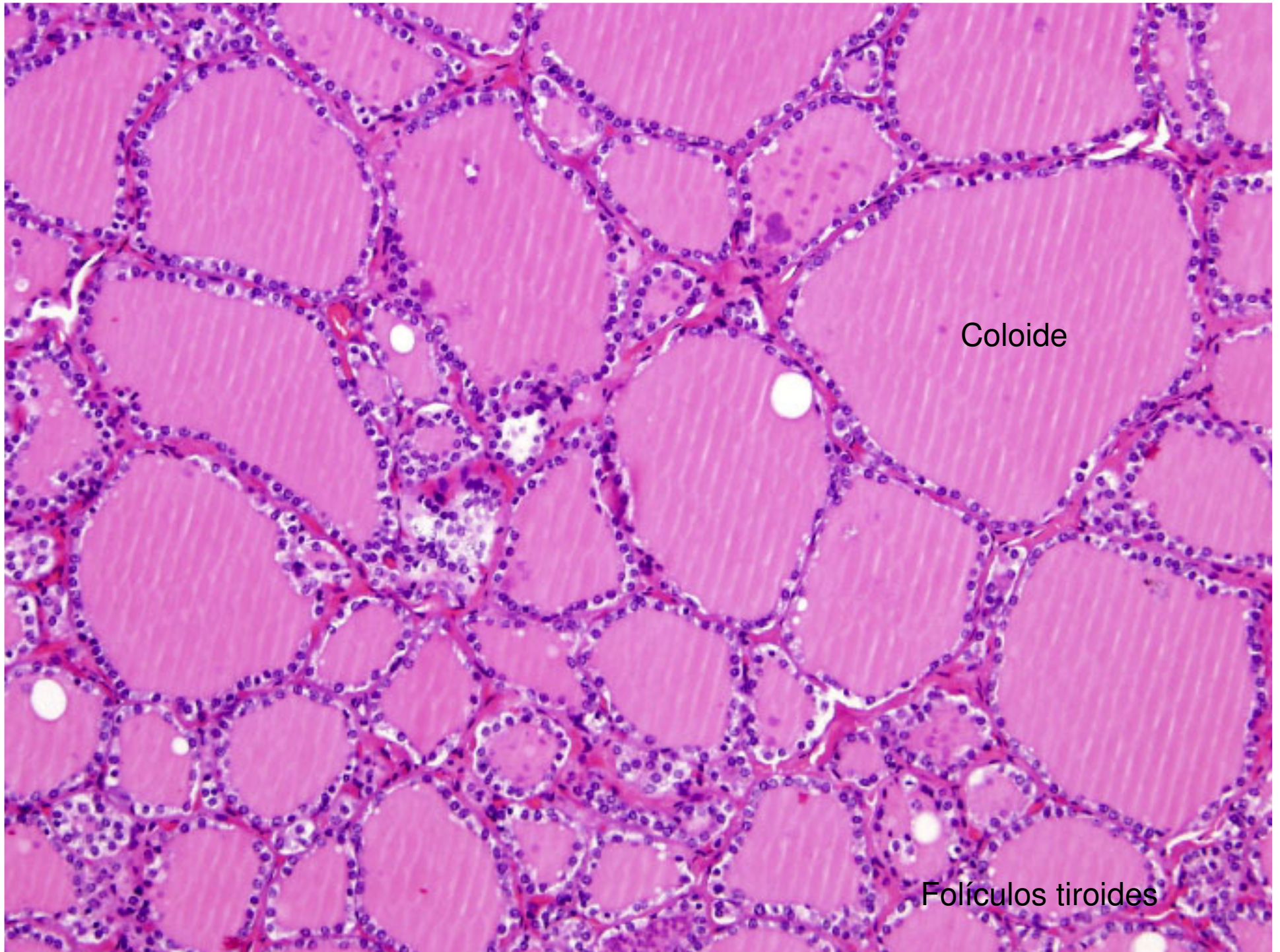
ATLAS DE MICROSCOPIA TIROIDES



ANATOMIA PATOLOGICA
FACULTAD DE MEDICINA

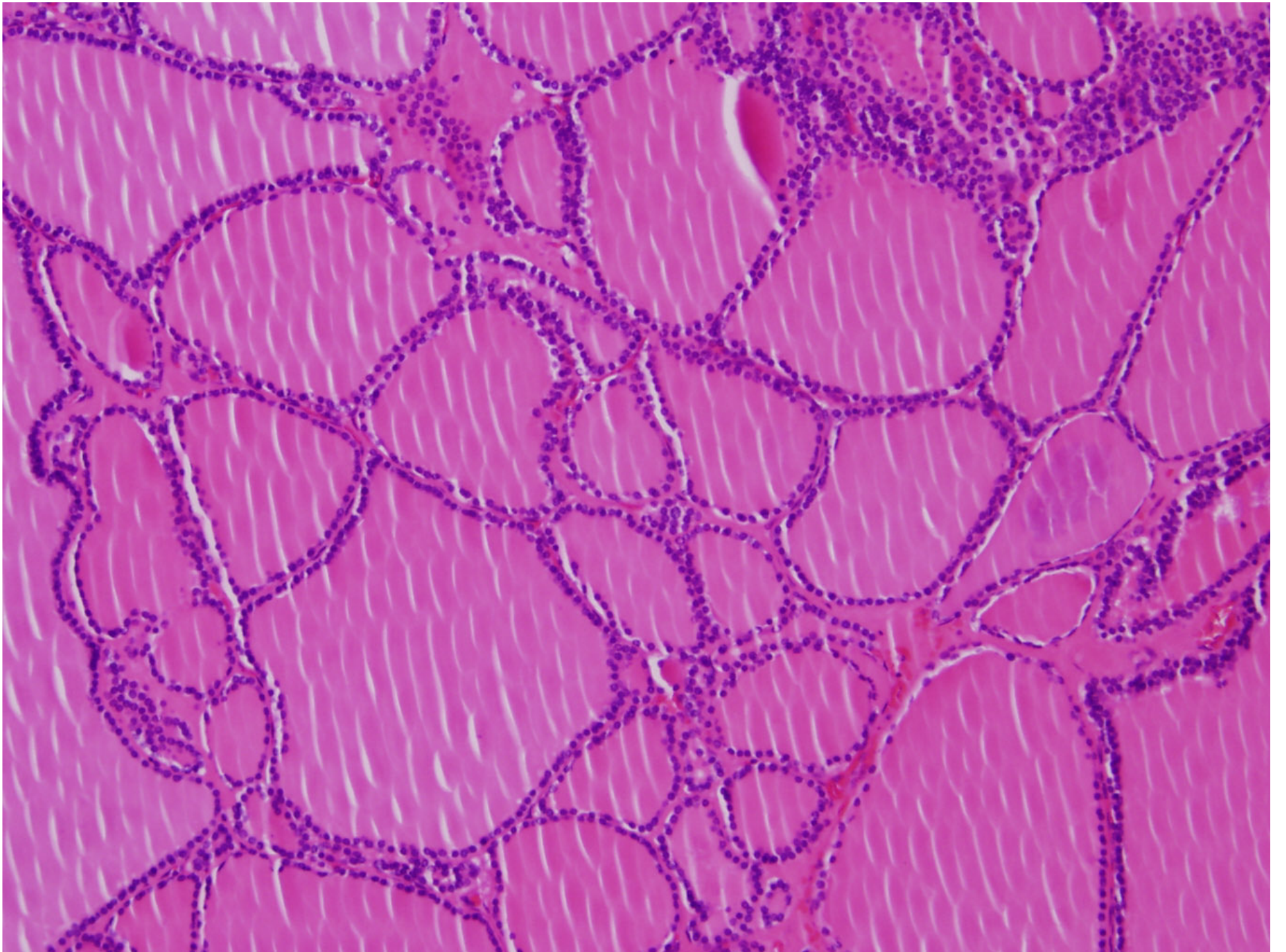


ANATOMÍA PATOLÓGICA

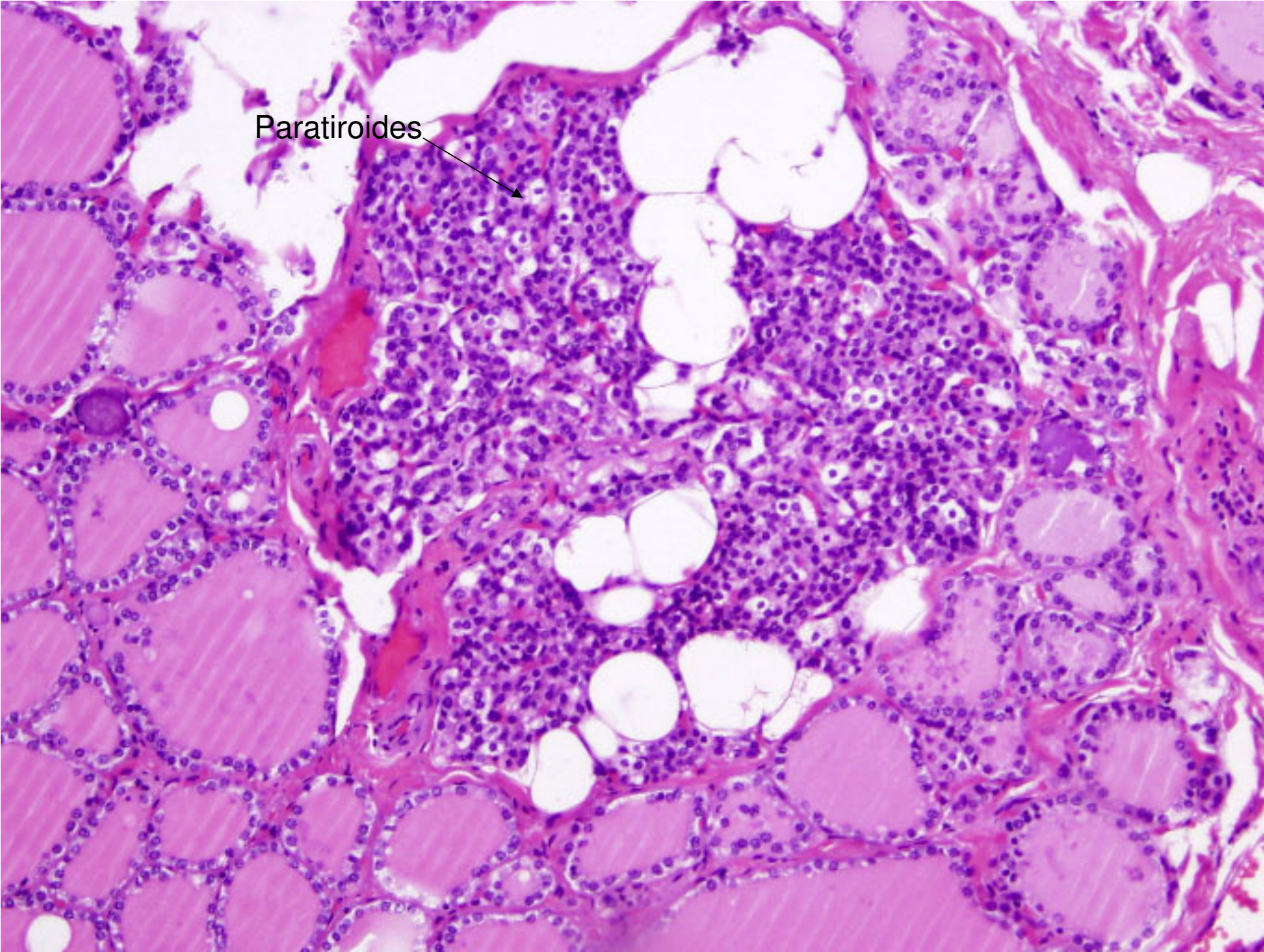


Coloide

Folículos tiroides



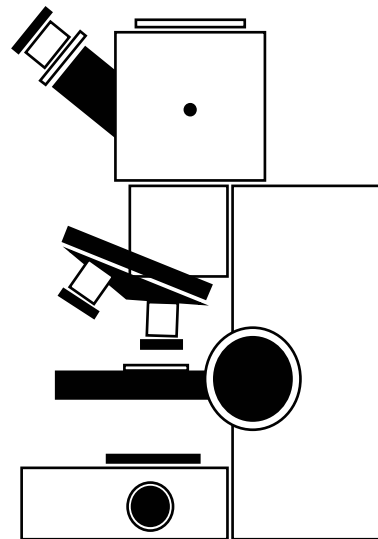
Paratiroides



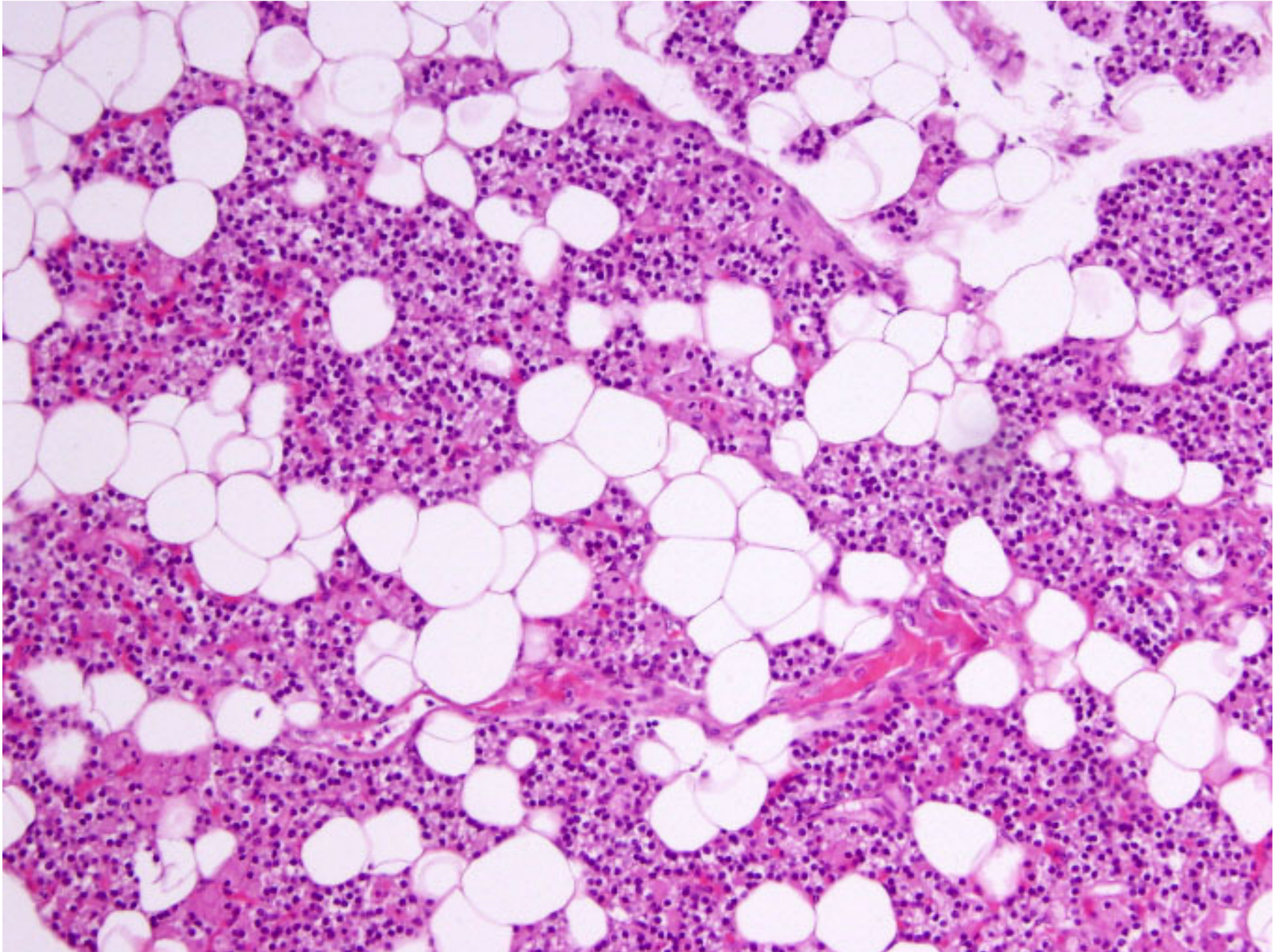
ATLAS DE MICROSCOPIA PARATIROIDES

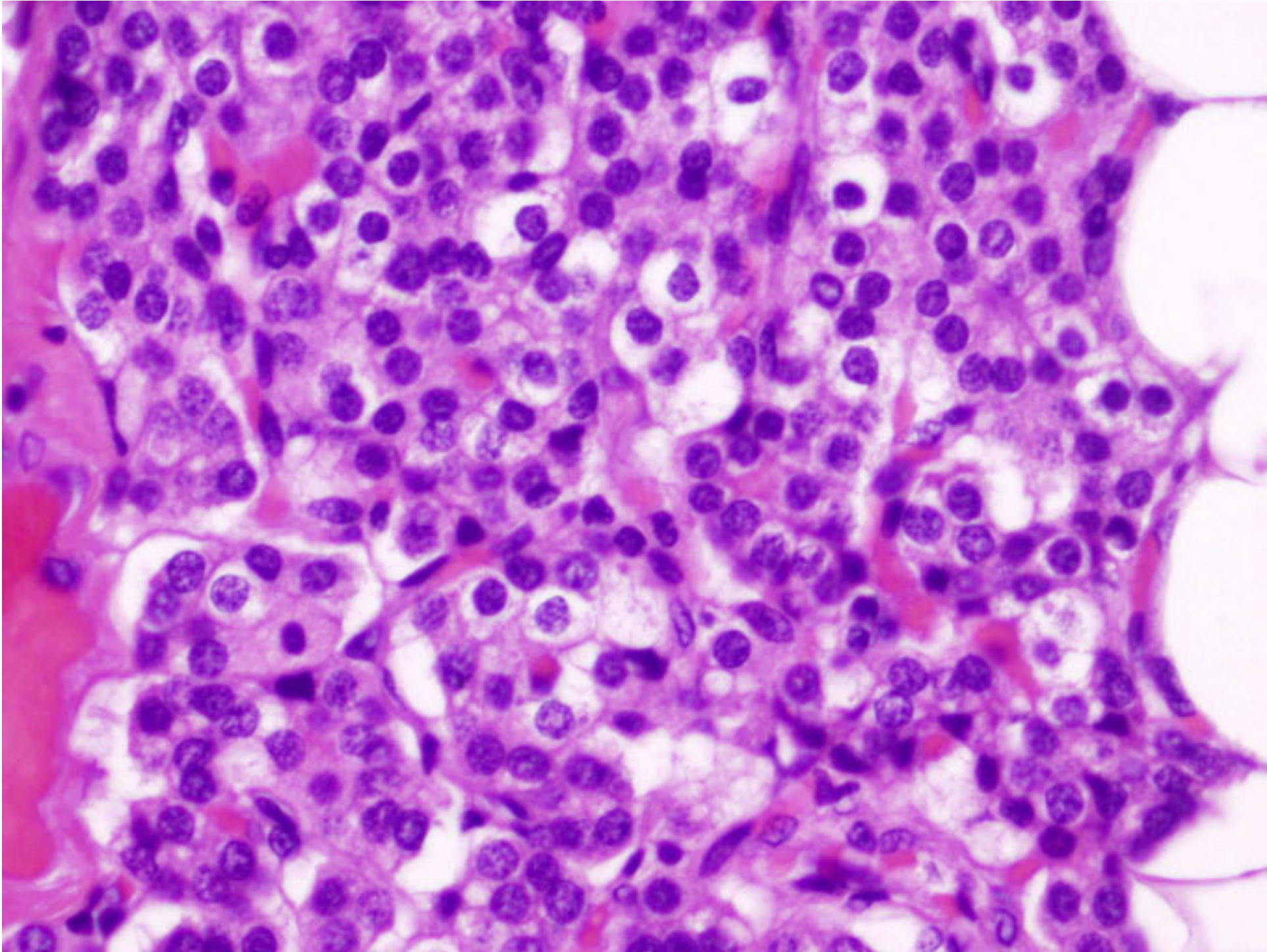


ANATOMIA PATOLOGICA
FACULTAD DE MEDICINA



ANATOMÍA PATOLÓGICA

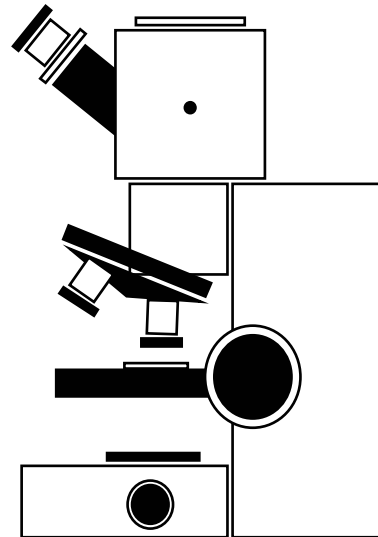




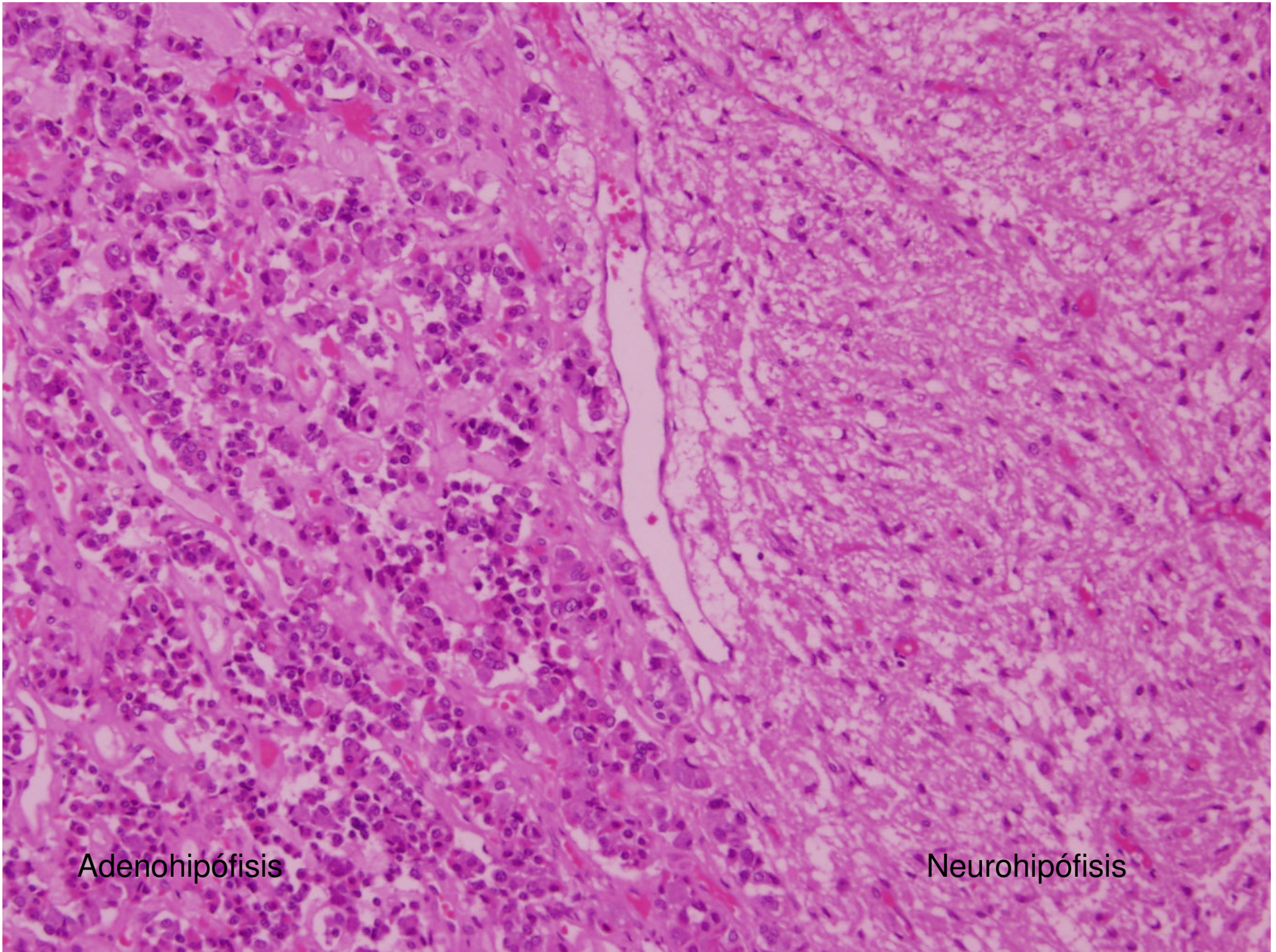
ATLAS DE MICROSCOPIA HIPÓFISIS



ANATOMIA PATOLÓGICA
FACULTAD DE MEDICINA

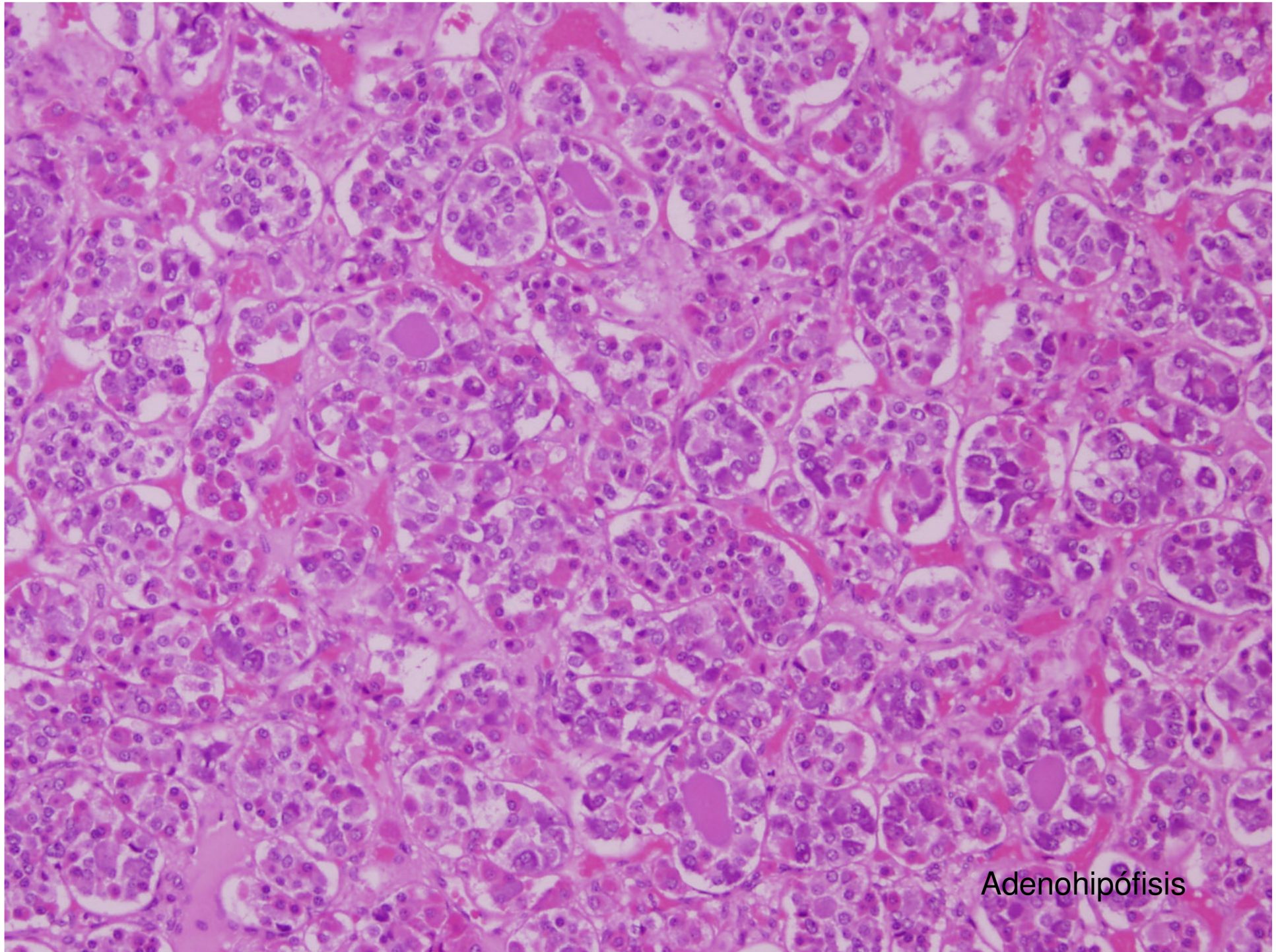


ANATOMÍA PATOLÓGICA

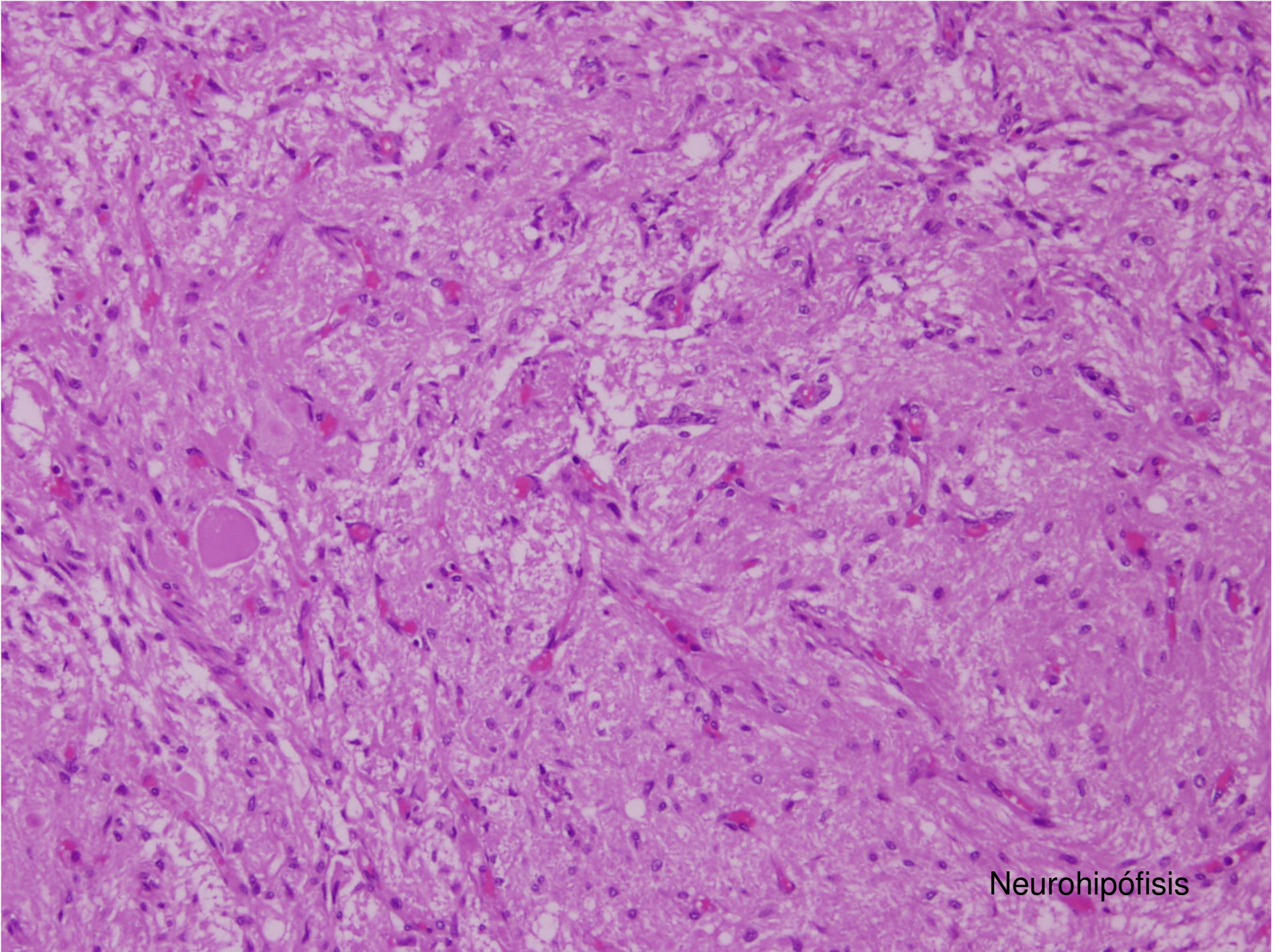


Adenohipófisis

Neurohipófisis



Adenohipófisis

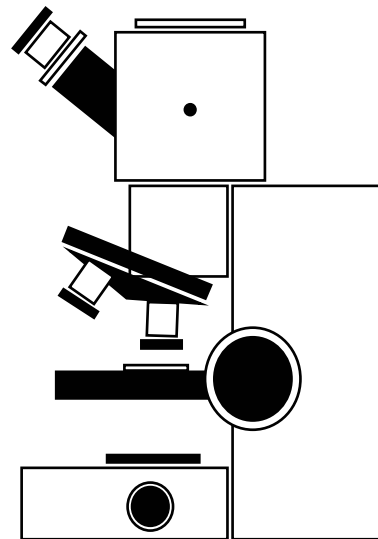


Neurohipófisis

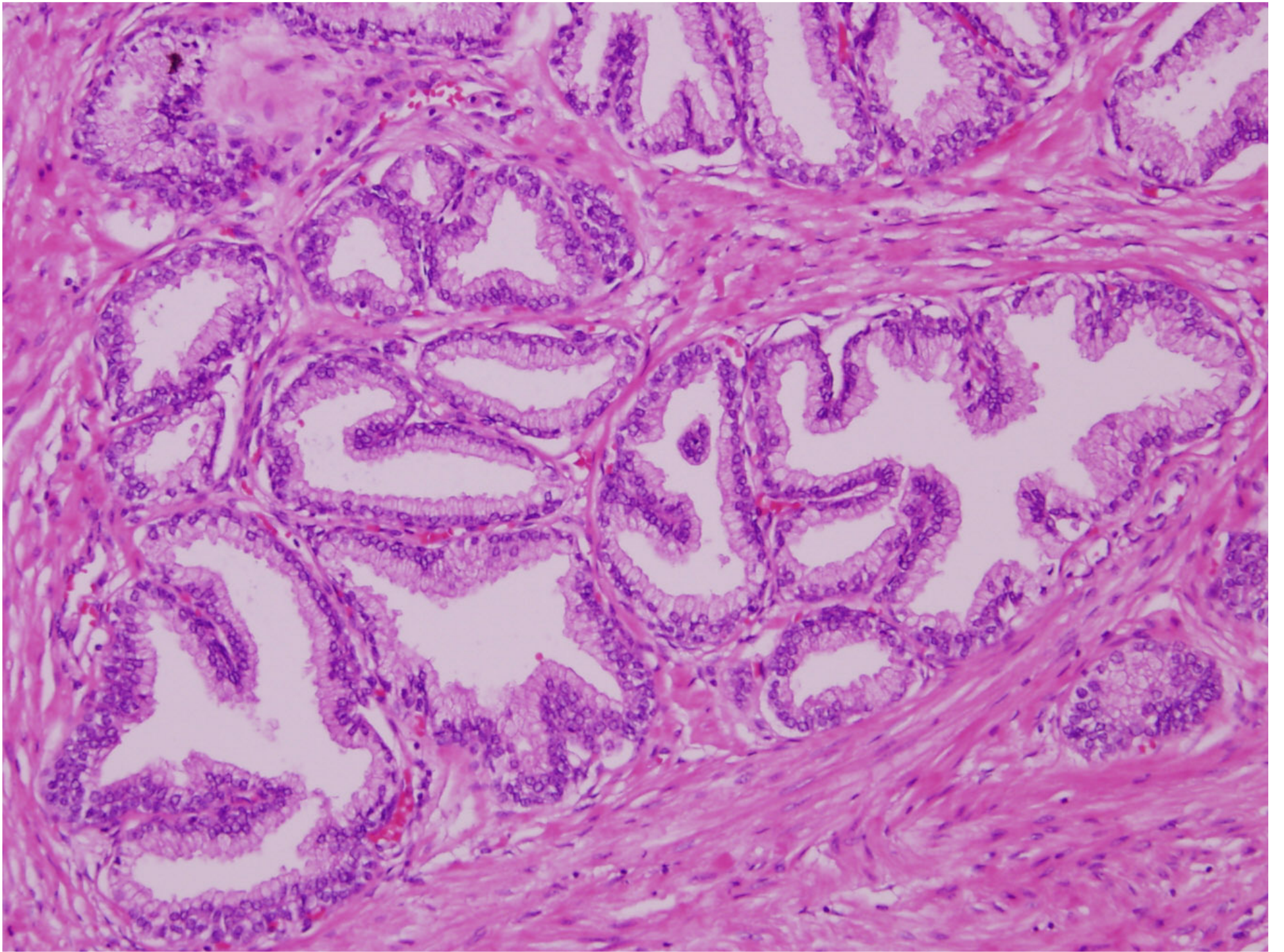
ATLAS DE MICROSCOPIA PRÓSTATA



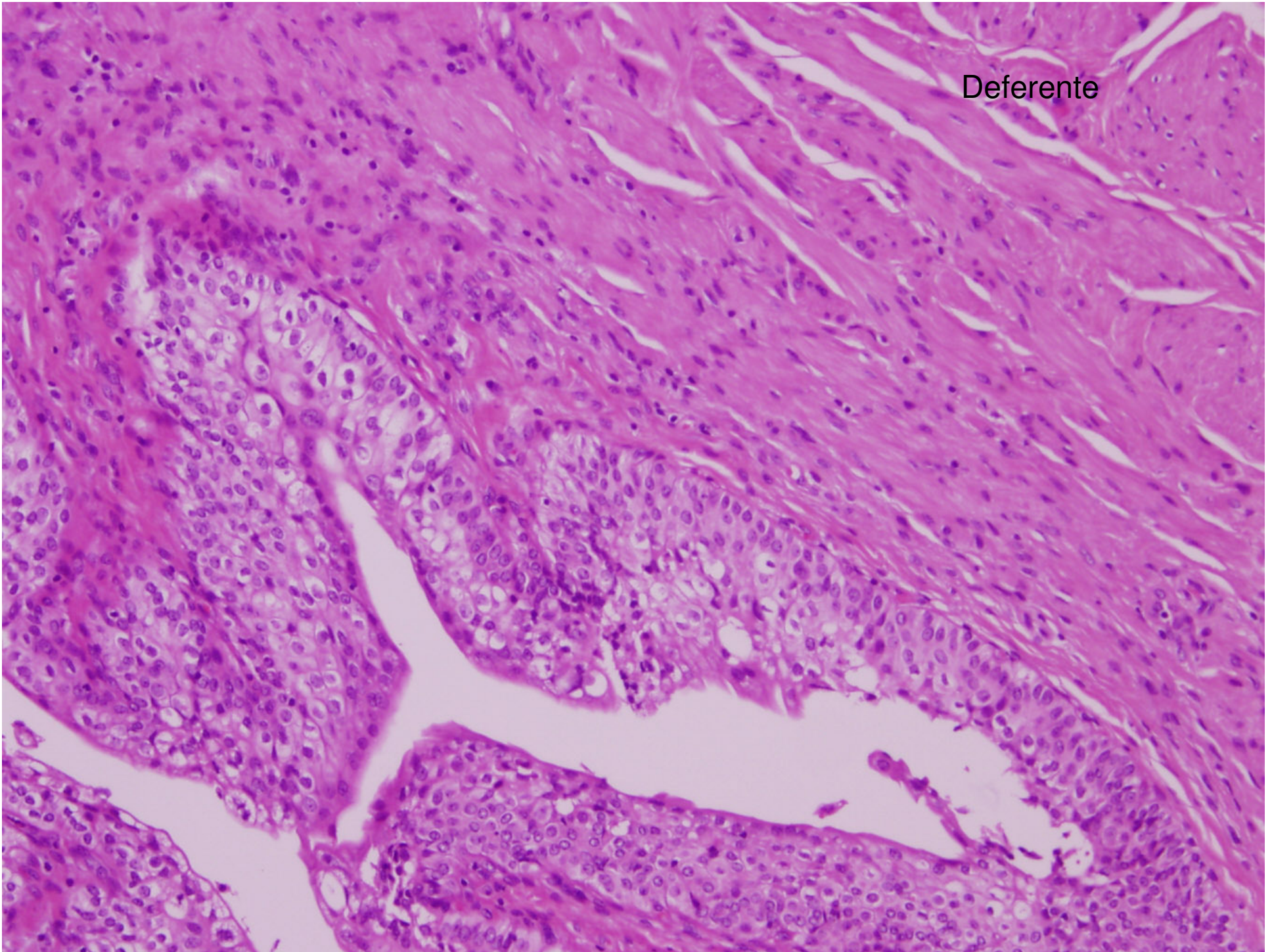
ANATOMIA PATOLÓGICA
FACULTAD DE MEDICINA



ANATOMÍA PATOLÓGICA



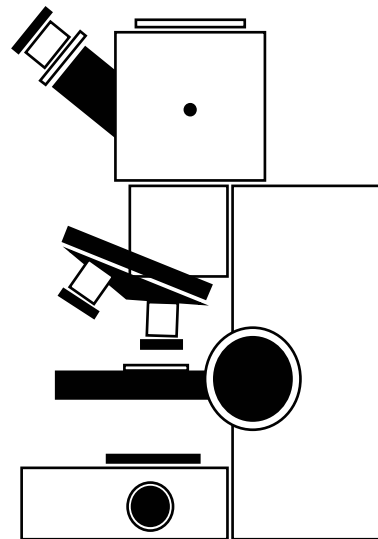
Deferente



ATLAS DE MICROSCOPIA ÚTERO

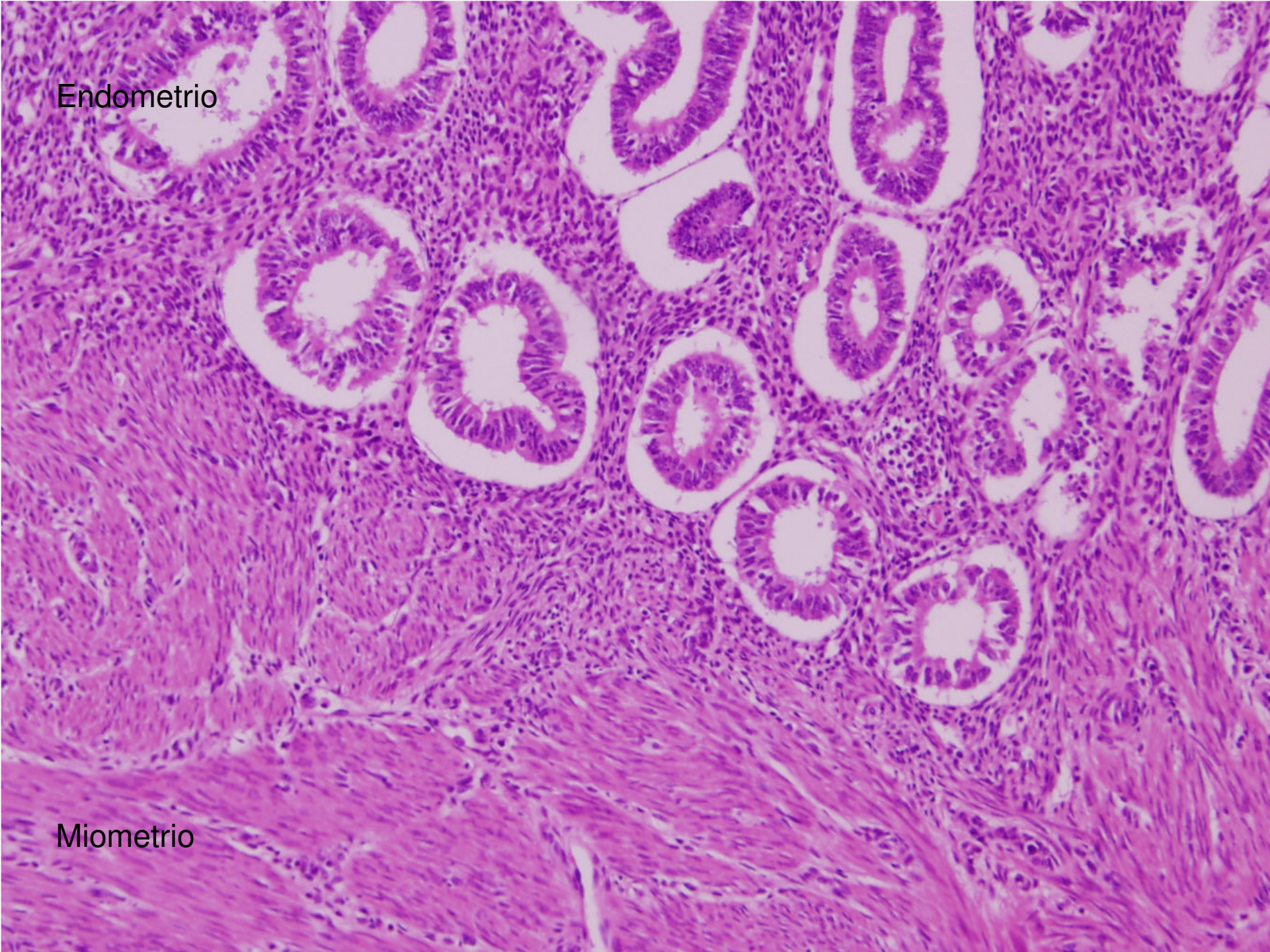


ANATOMIA PATOLÓGICA
FACULTAD DE MEDICINA



ANATOMÍA PATOLÓGICA

Endometrio

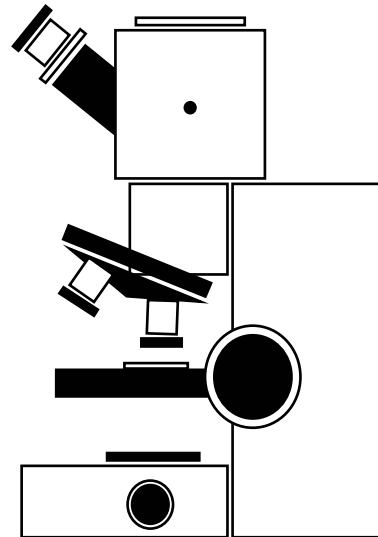


Miometrio

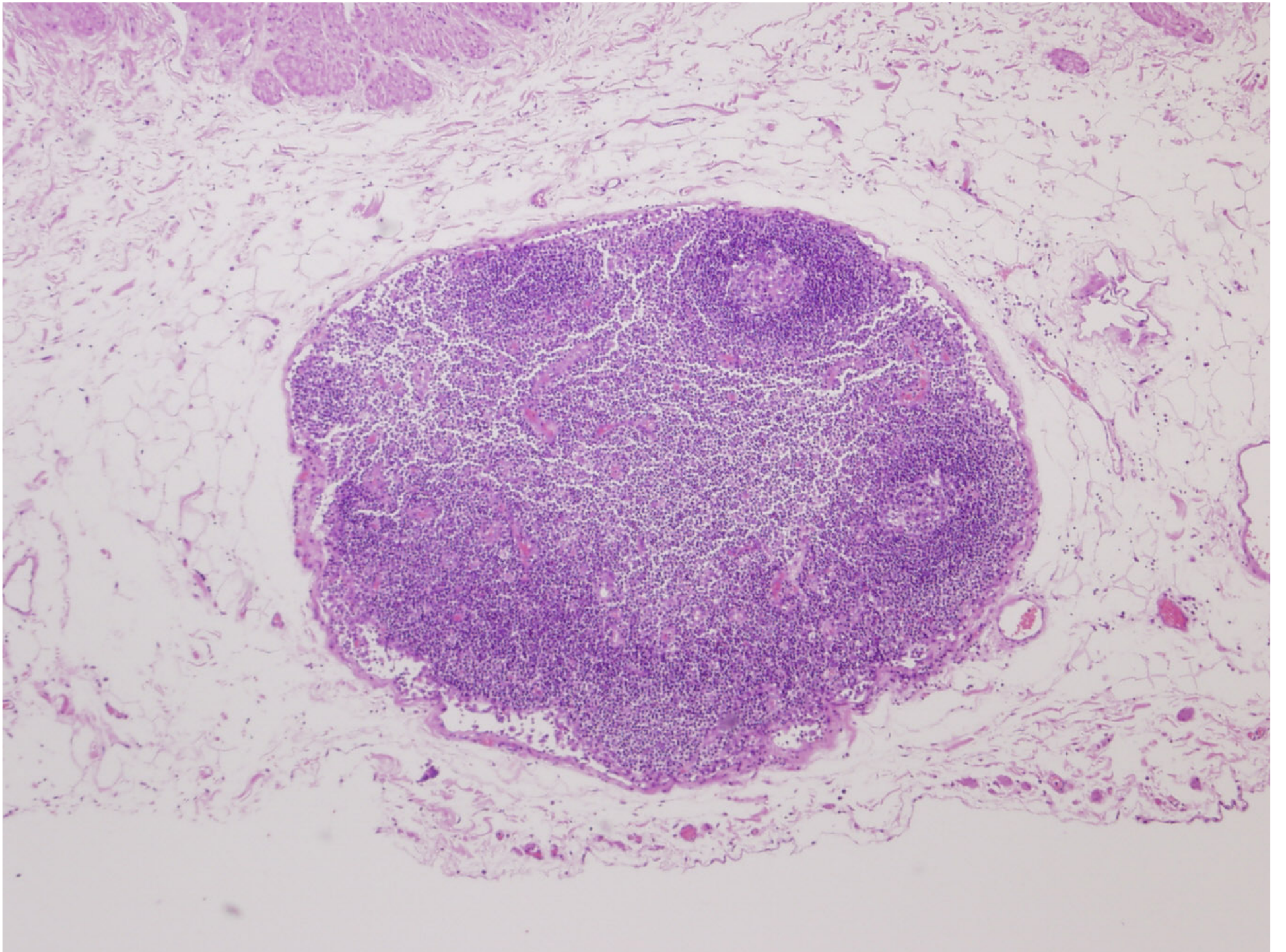
ATLAS DE MICROSCOPIA GANGLIO LINFÁTICO

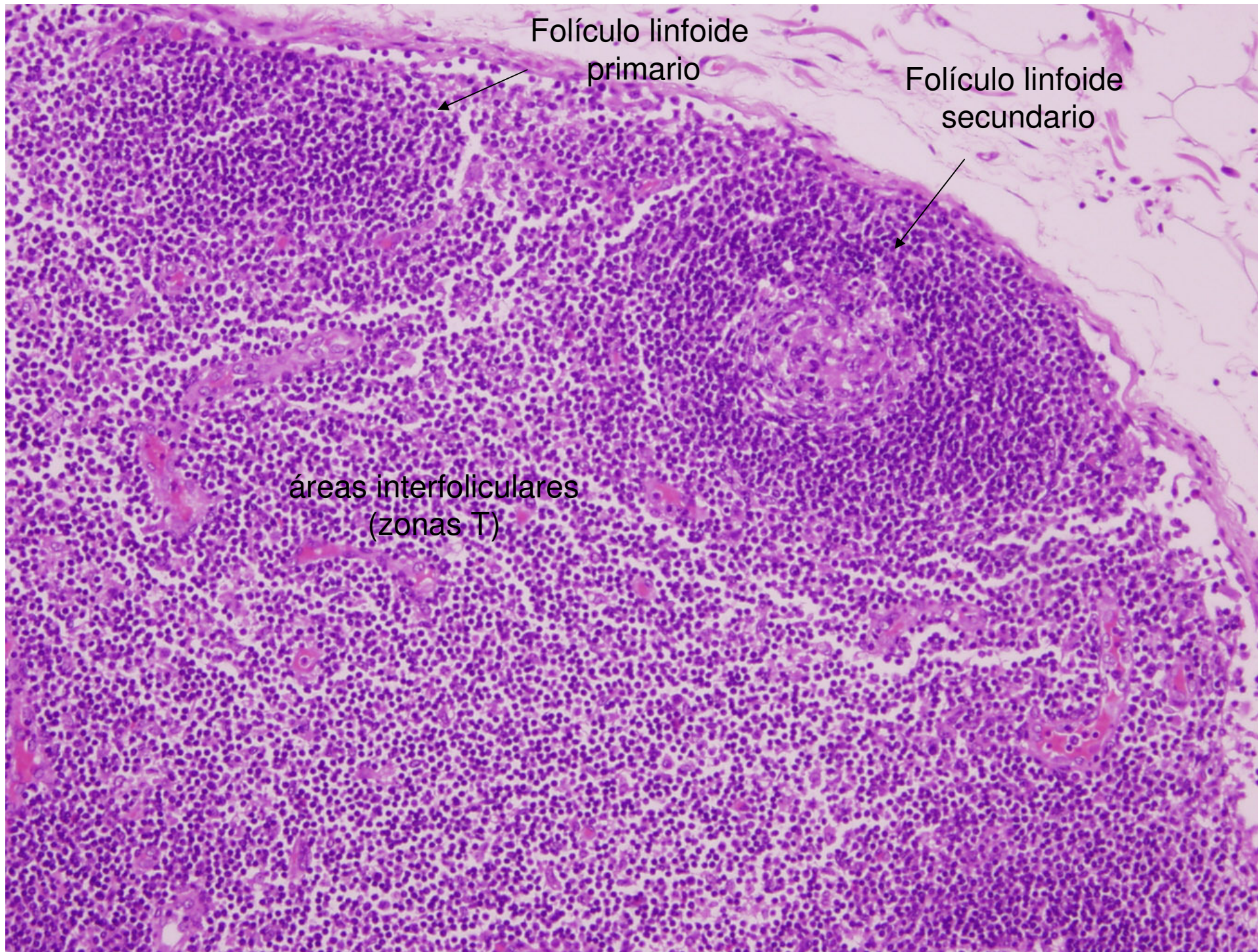


ANATOMIA PATOLÓGICA
FACULTAD DE MEDICINA



ANATOMÍA PATOLÓGICA

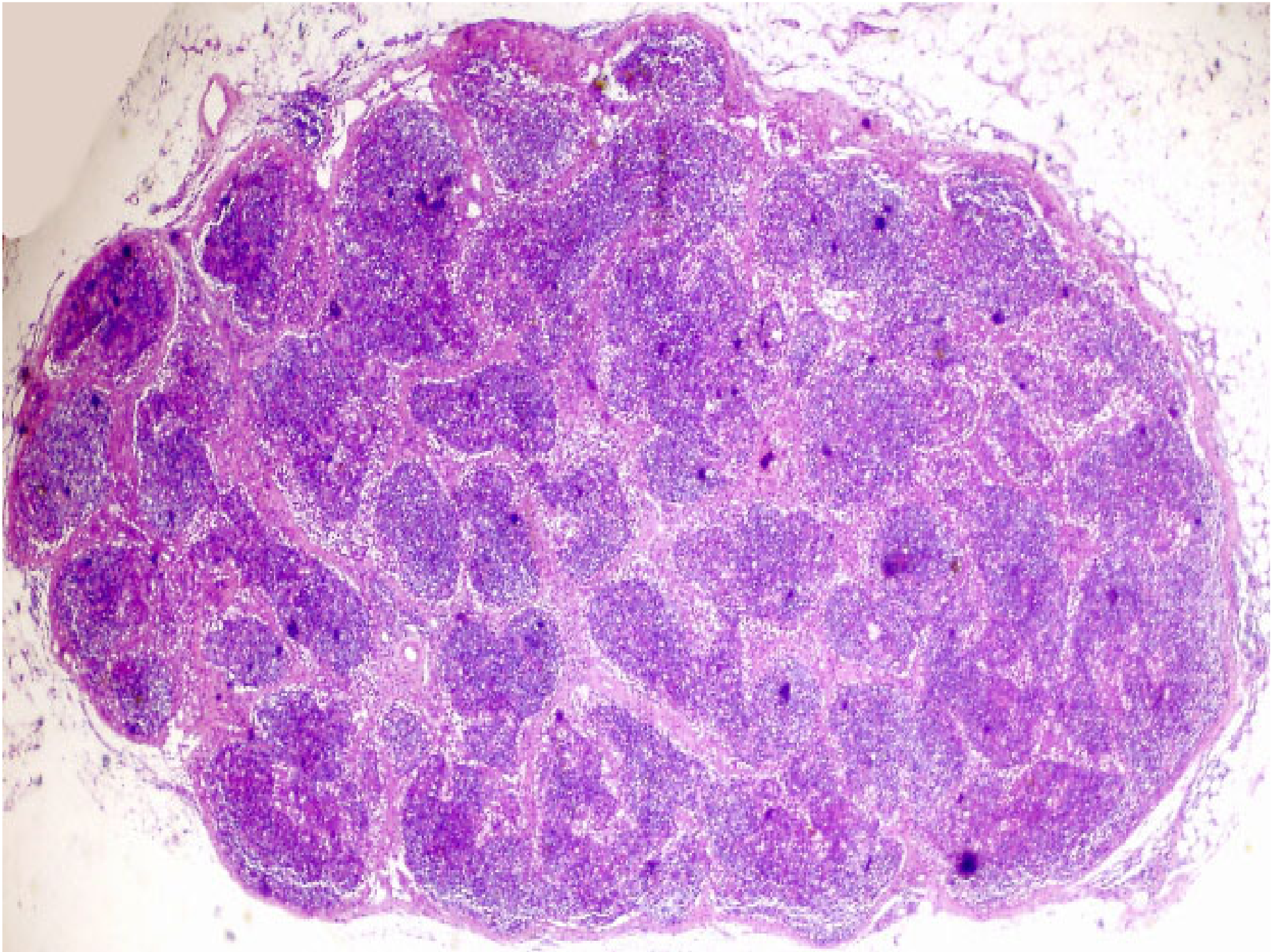


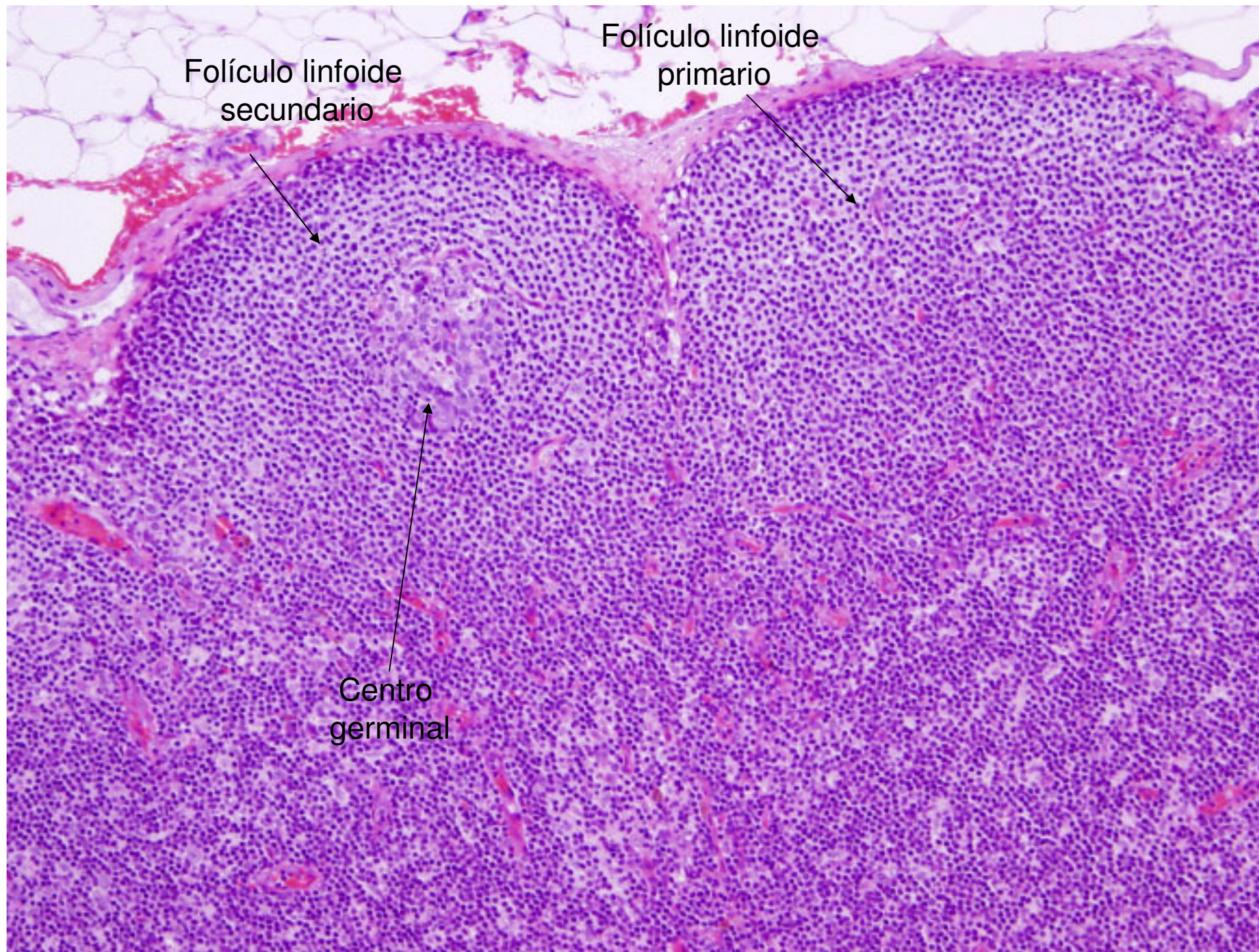


Folículo linfoide
primario

Folículo linfoide
secundario

áreas interfoliculares
(zonas T)

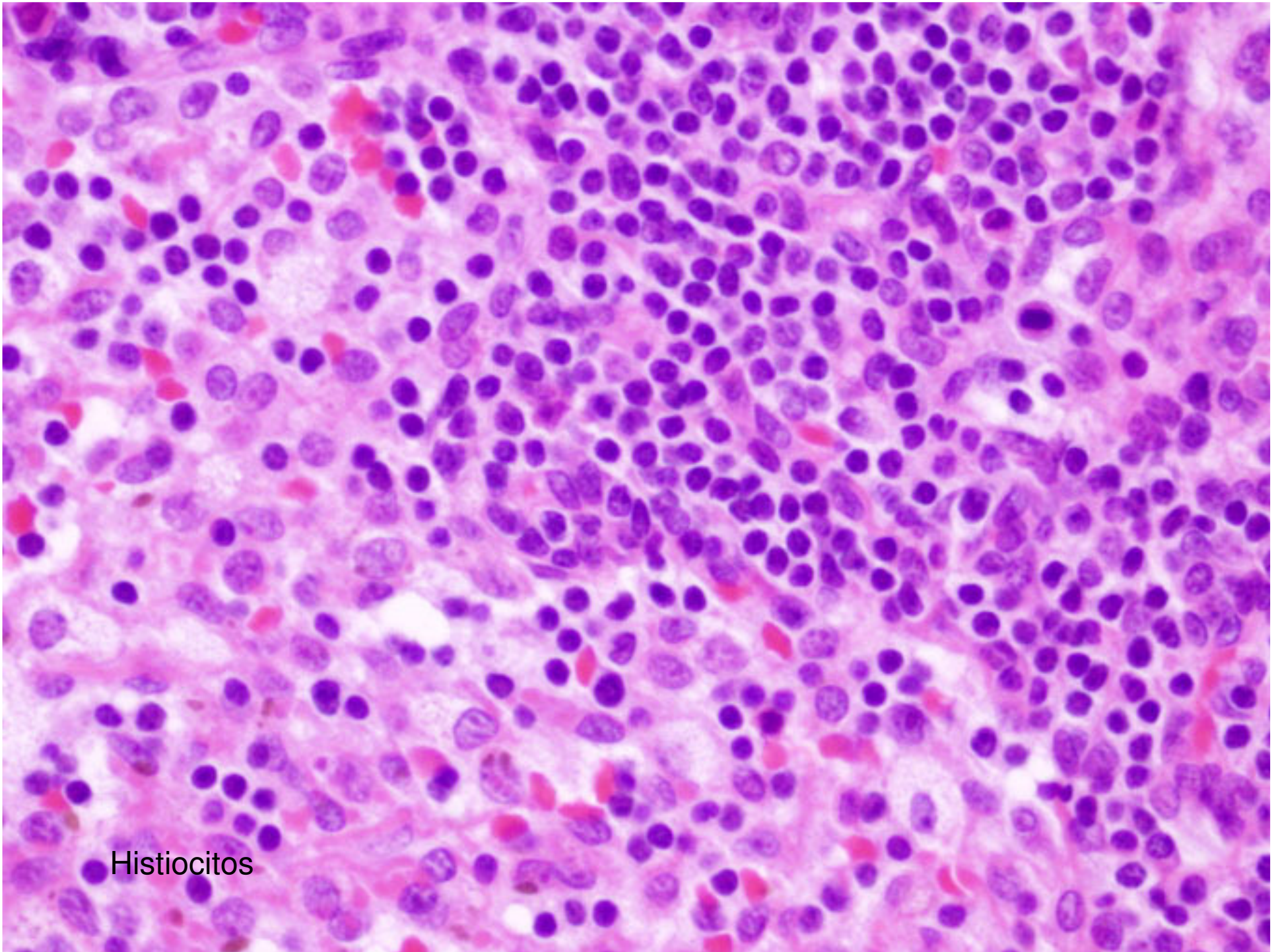




Folículo linfoide
secundario

Folículo linfoide
primario

Centro
germinal

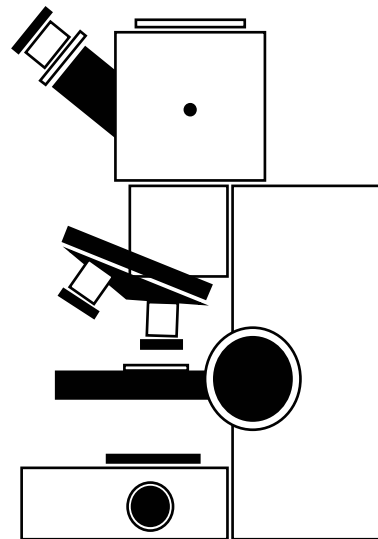


Histiocitos

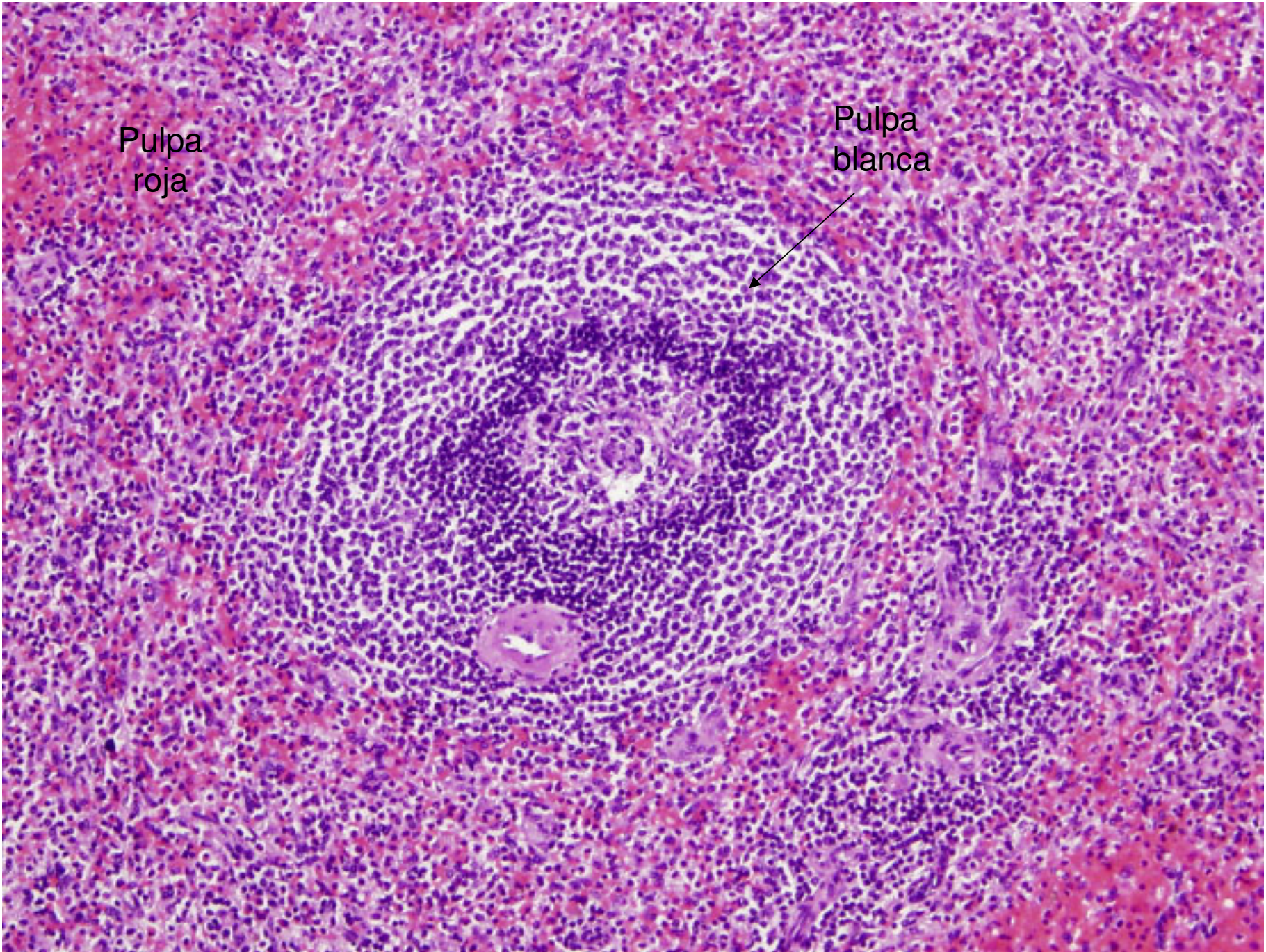
ATLAS DE MICROSCOPIA BAZO



ANATOMIA PATOLOGICA
FACULTAD DE MEDICINA



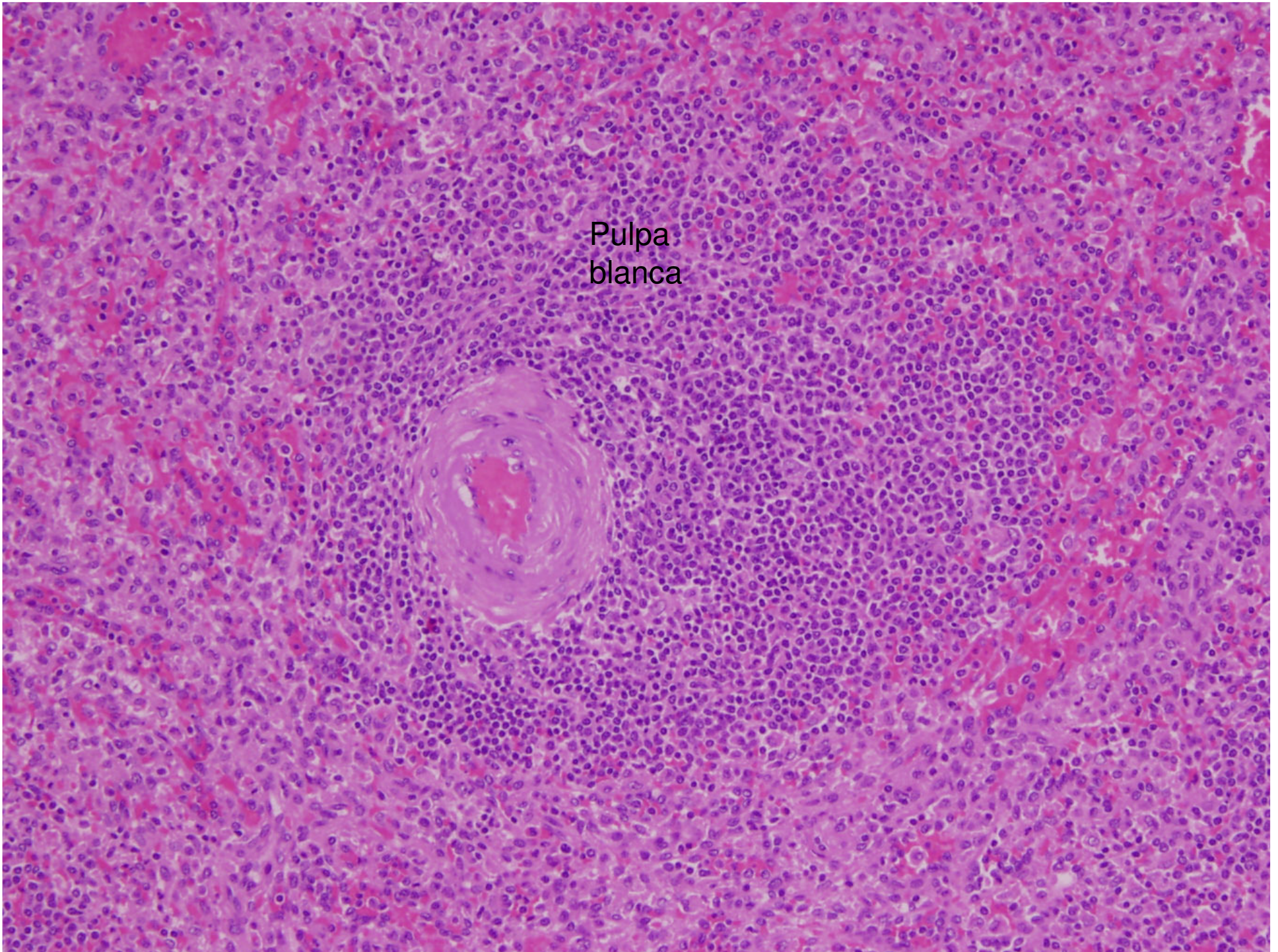
ANATOMÍA PATOLÓGICA

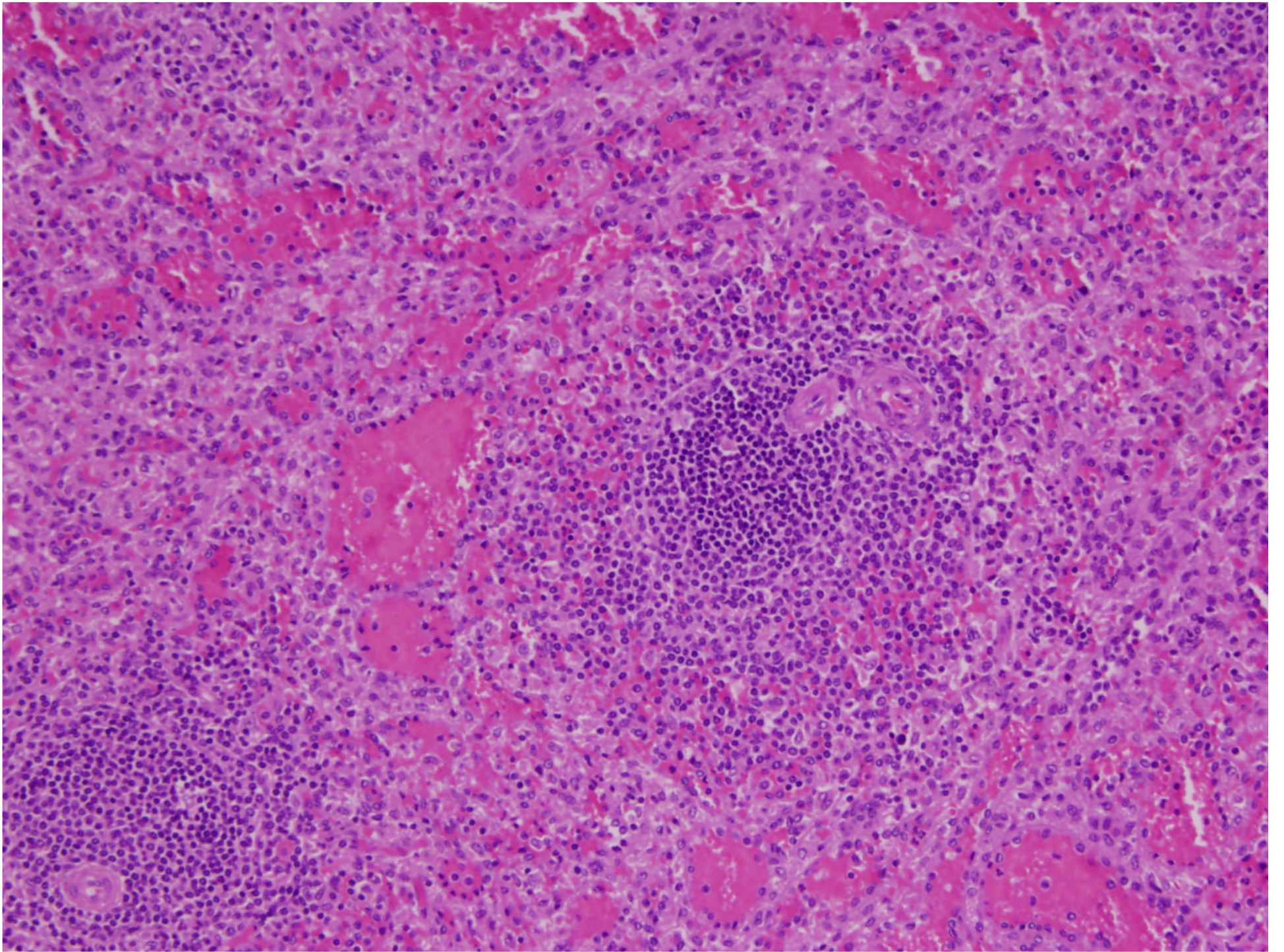


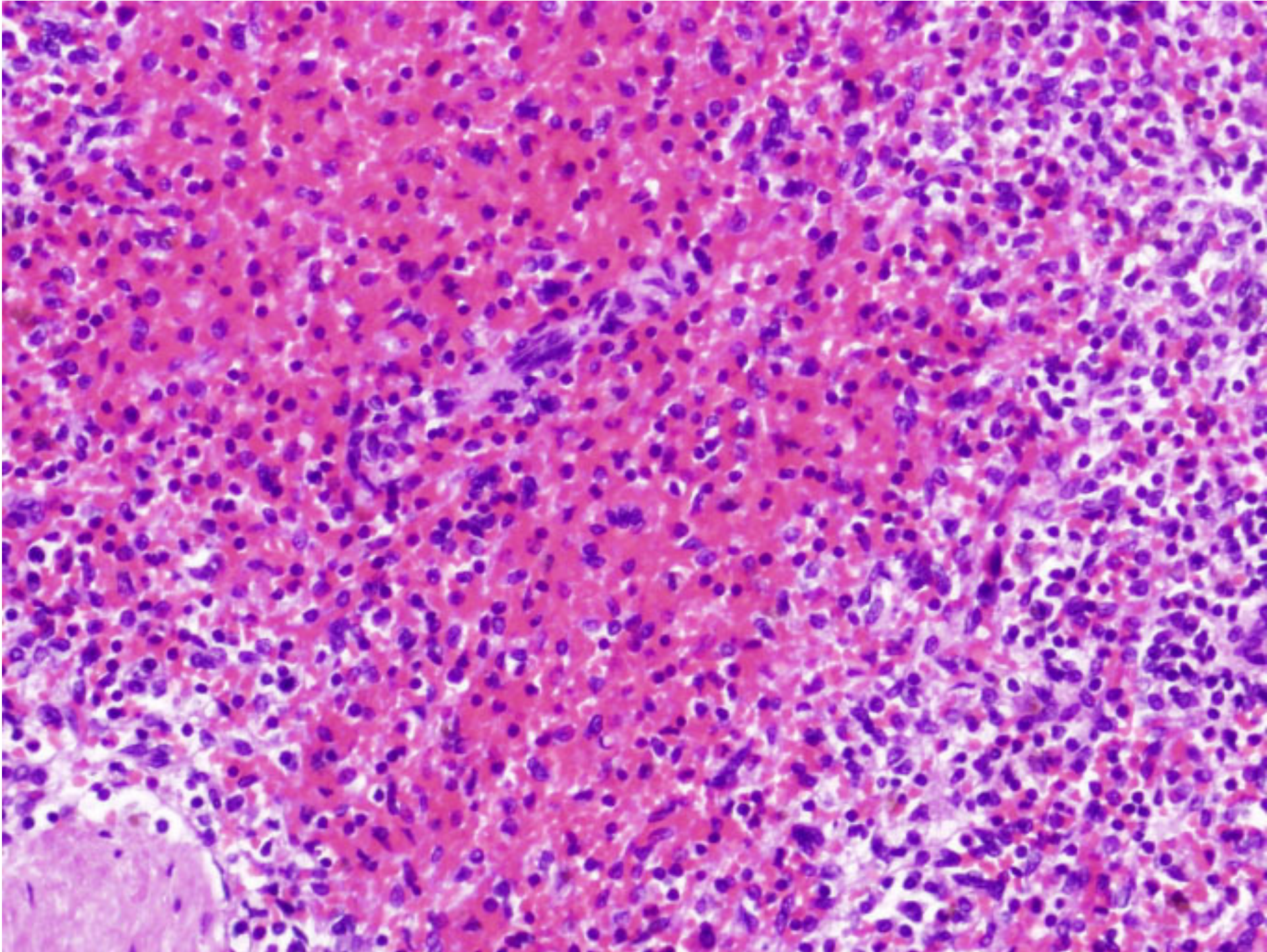
Pulpa
roja

Pulpa
blanca

Pulpa
blanca



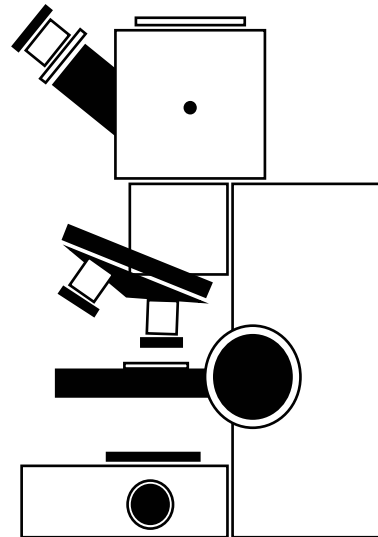




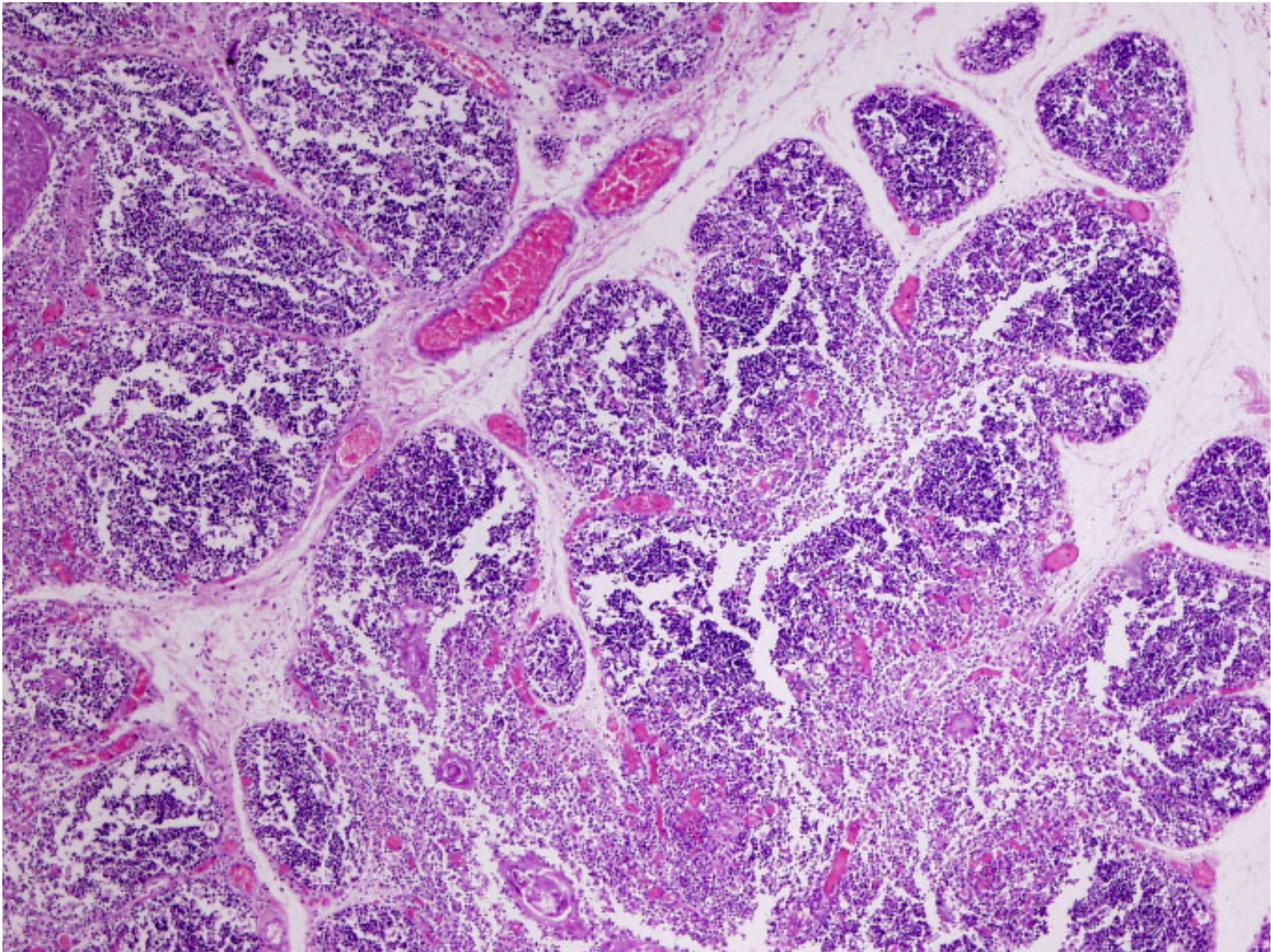
ATLAS DE MICROSCOPIA TIMO (ADULTO)

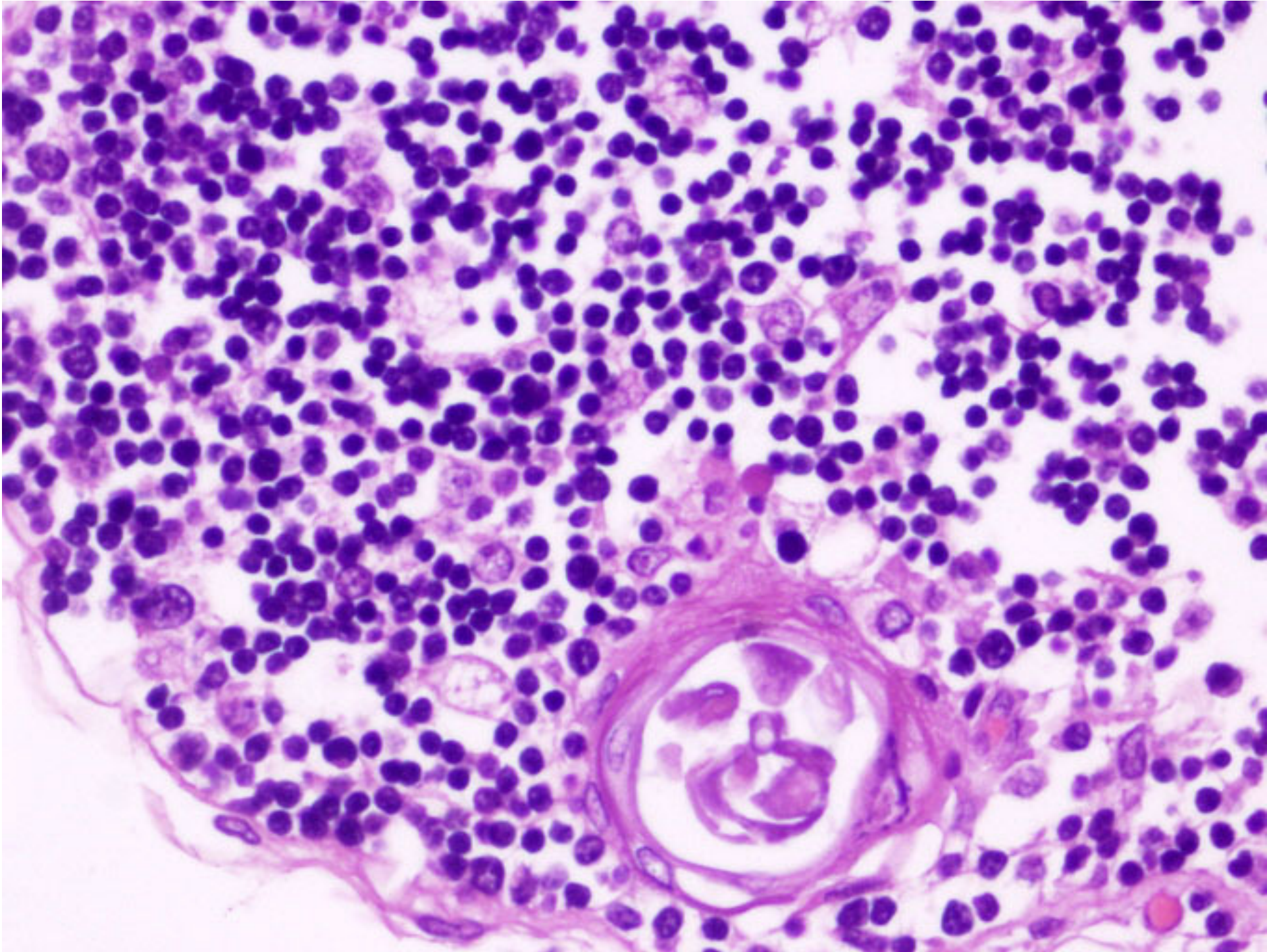


ANATOMIA PATOLÓGICA
FACULTAD DE MEDICINA



ANATOMÍA PATOLÓGICA

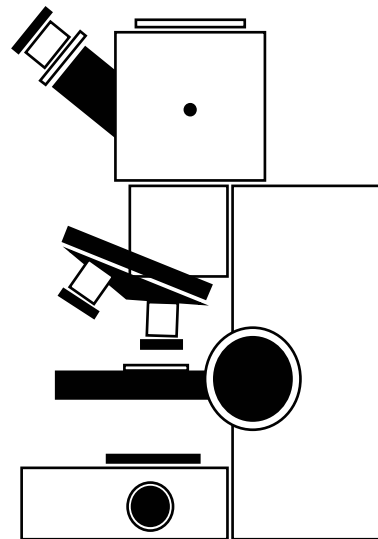




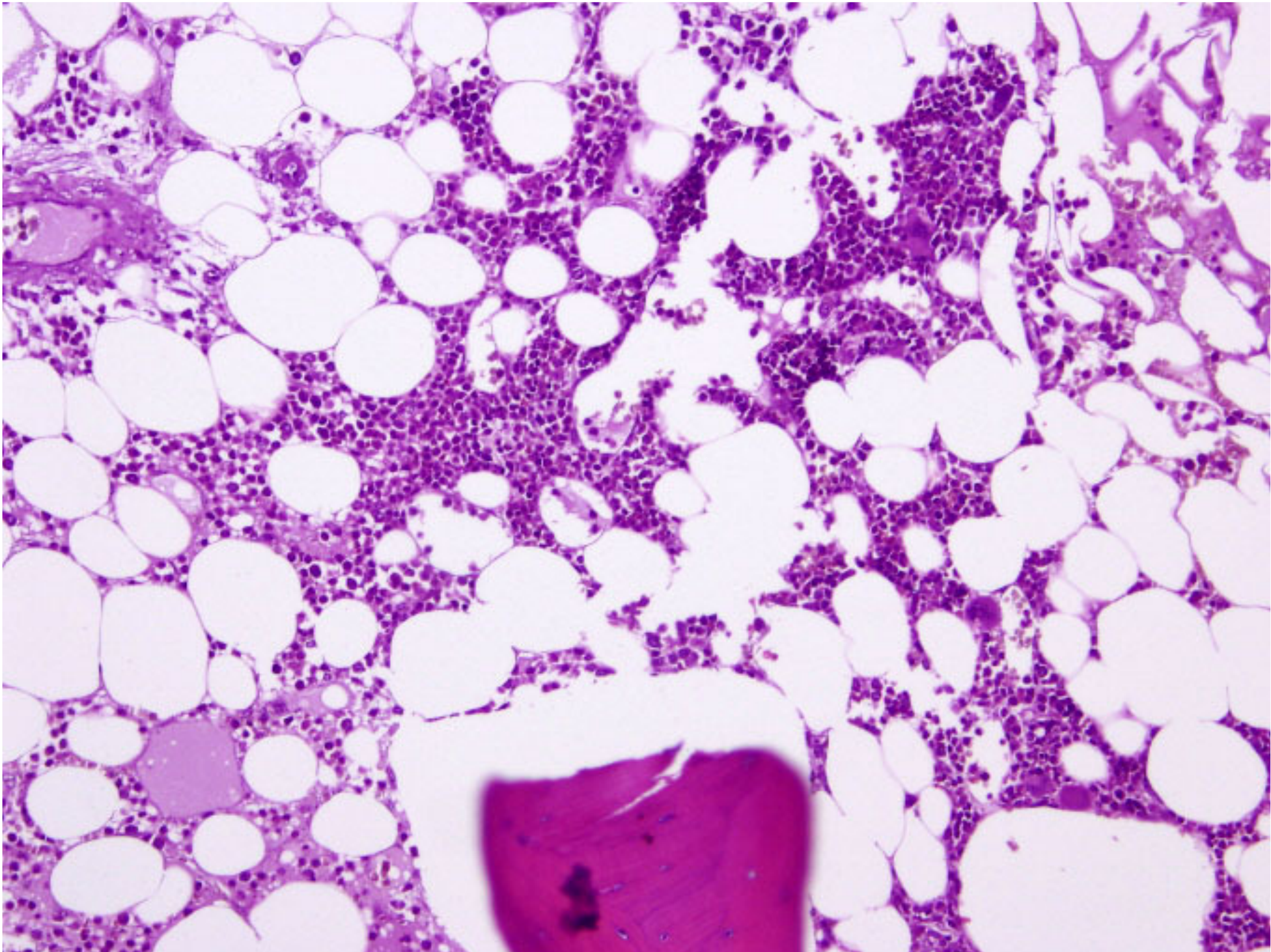
ATLAS DE MICROSCOPIA MÉDULA ÓSEA

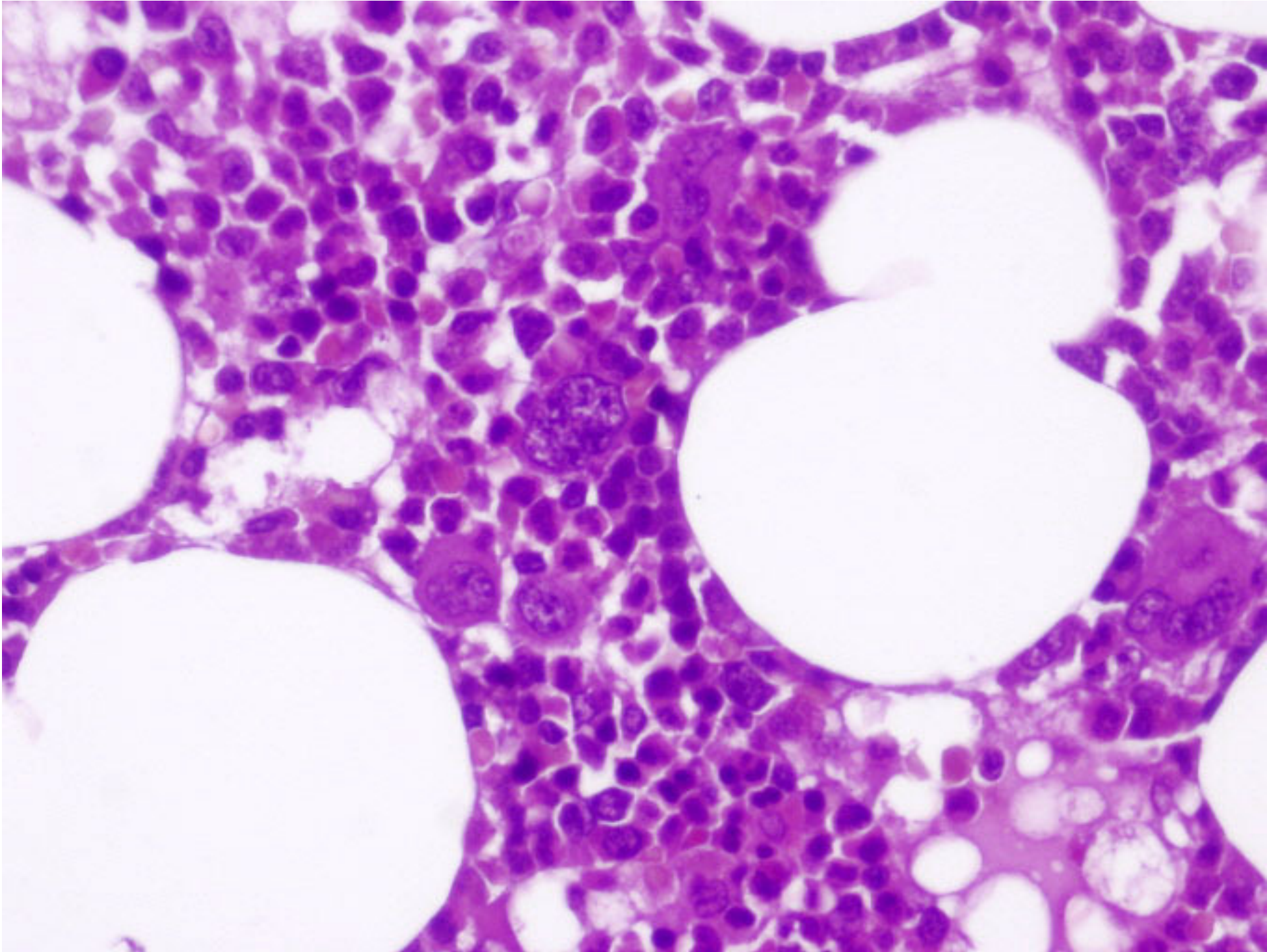


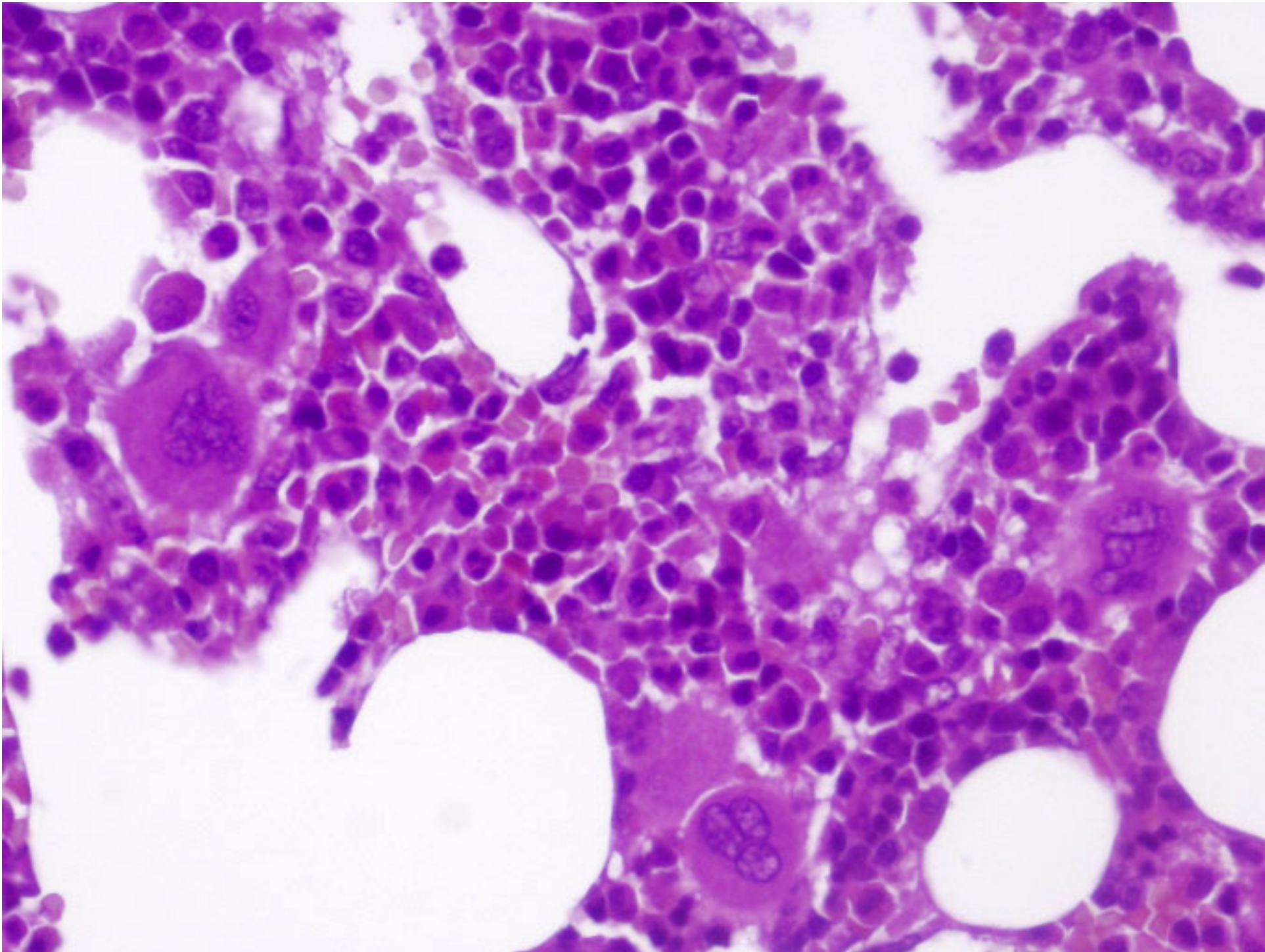
ANATOMIA PATOLÓGICA
FACULTAD DE MEDICINA



ANATOMÍA PATOLÓGICA



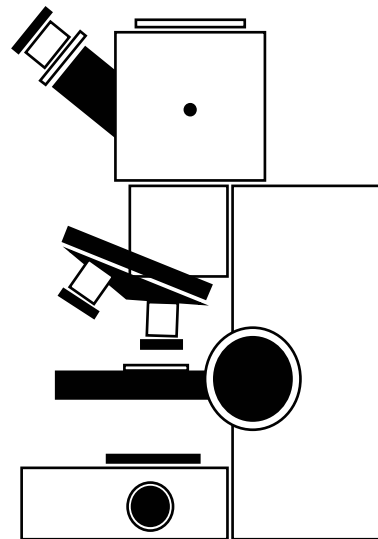




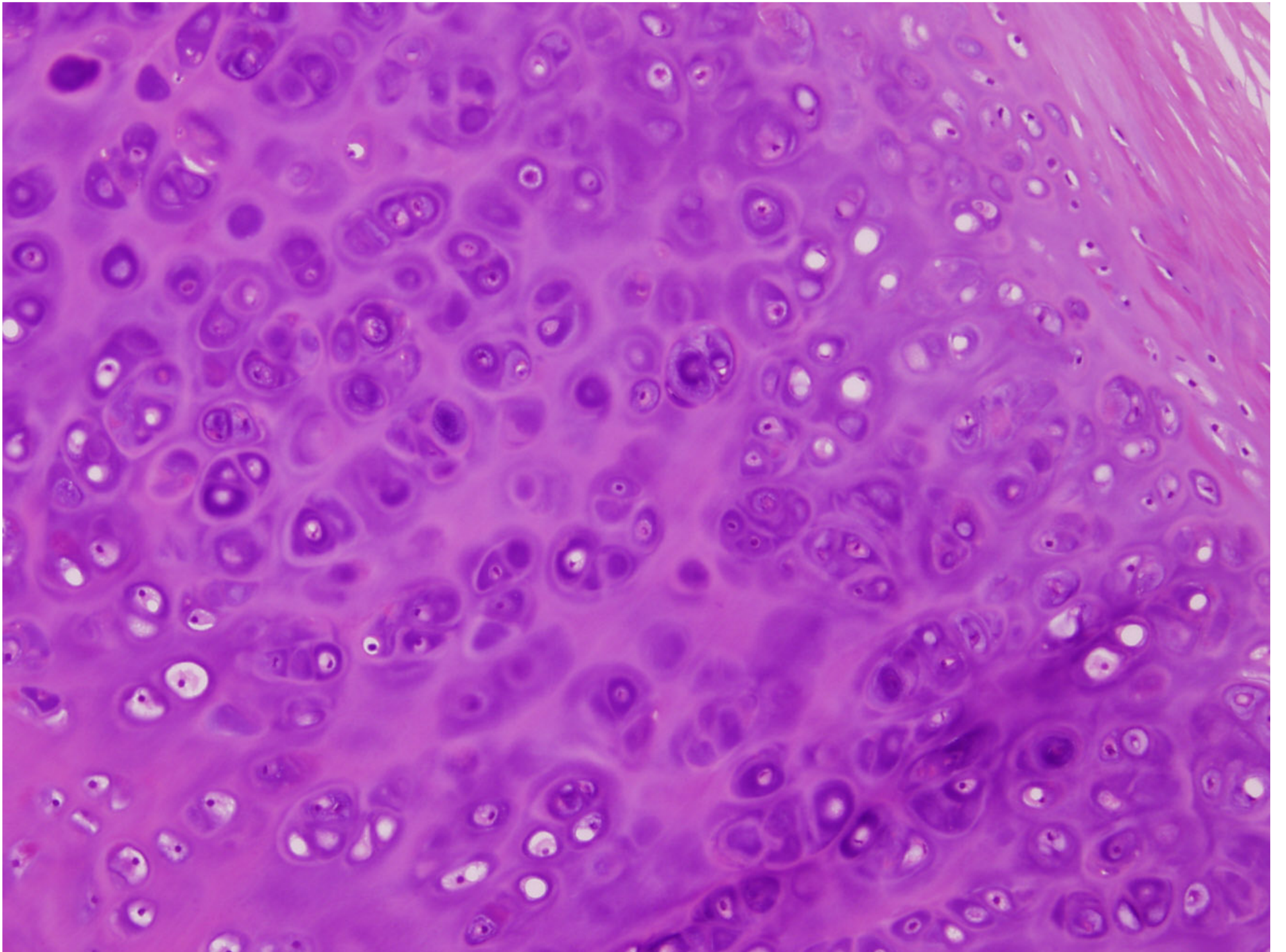
ATLAS DE MICROSCOPIA CARTÍLAGO HIALINO



ANATOMIA PATOLOGICA
FACULTAD DE MEDICINA



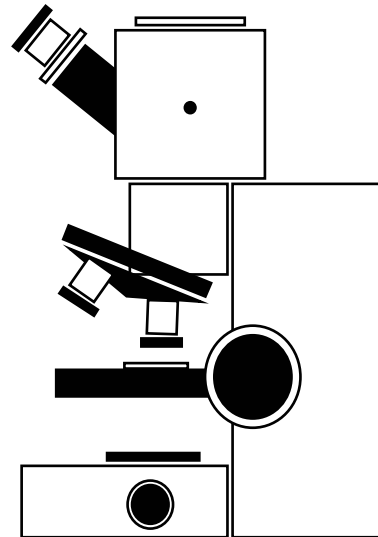
ANATOMÍA PATOLÓGICA



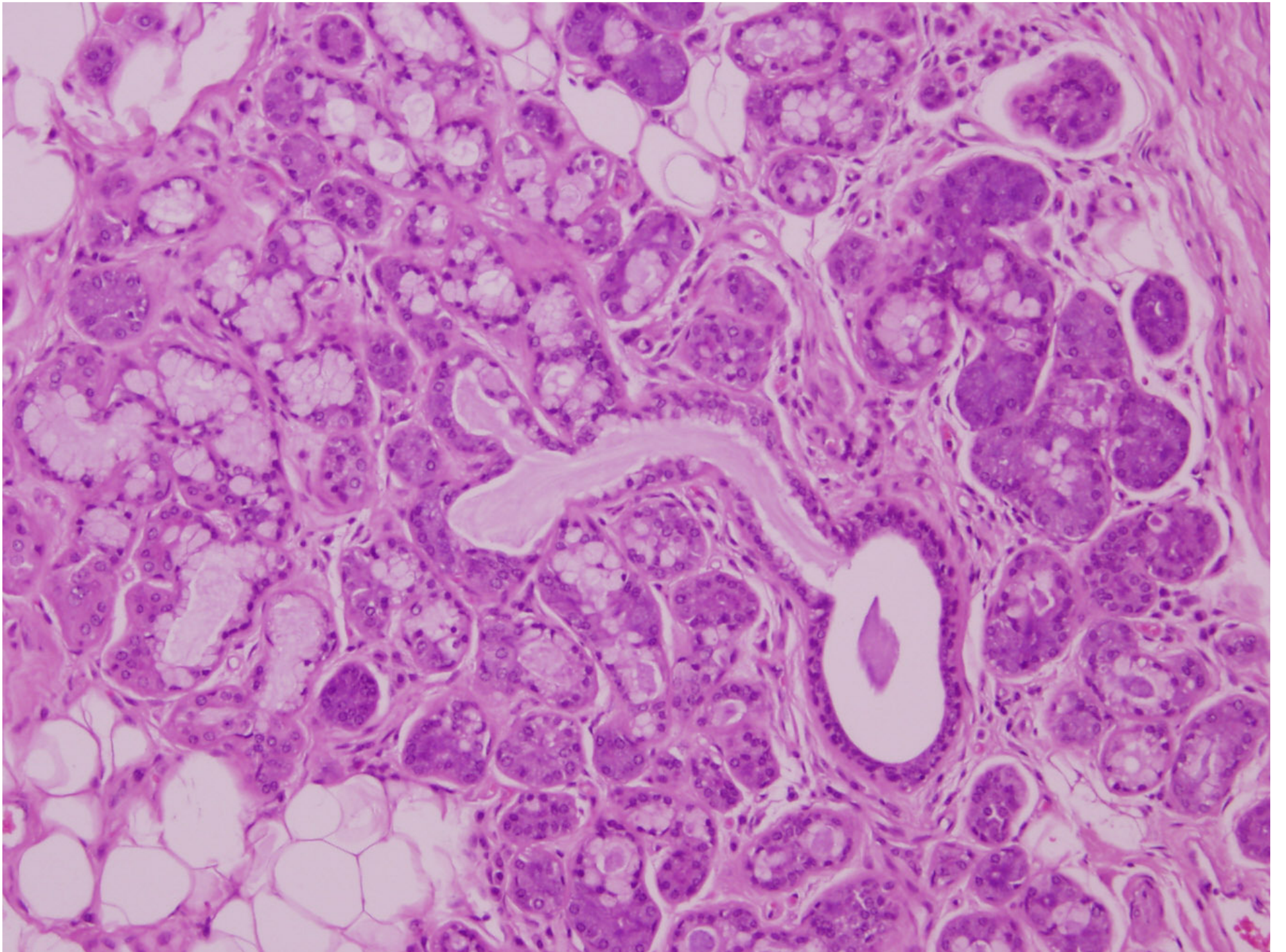
ATLAS DE MICROSCOPIA GLANDULAS MIXTAS

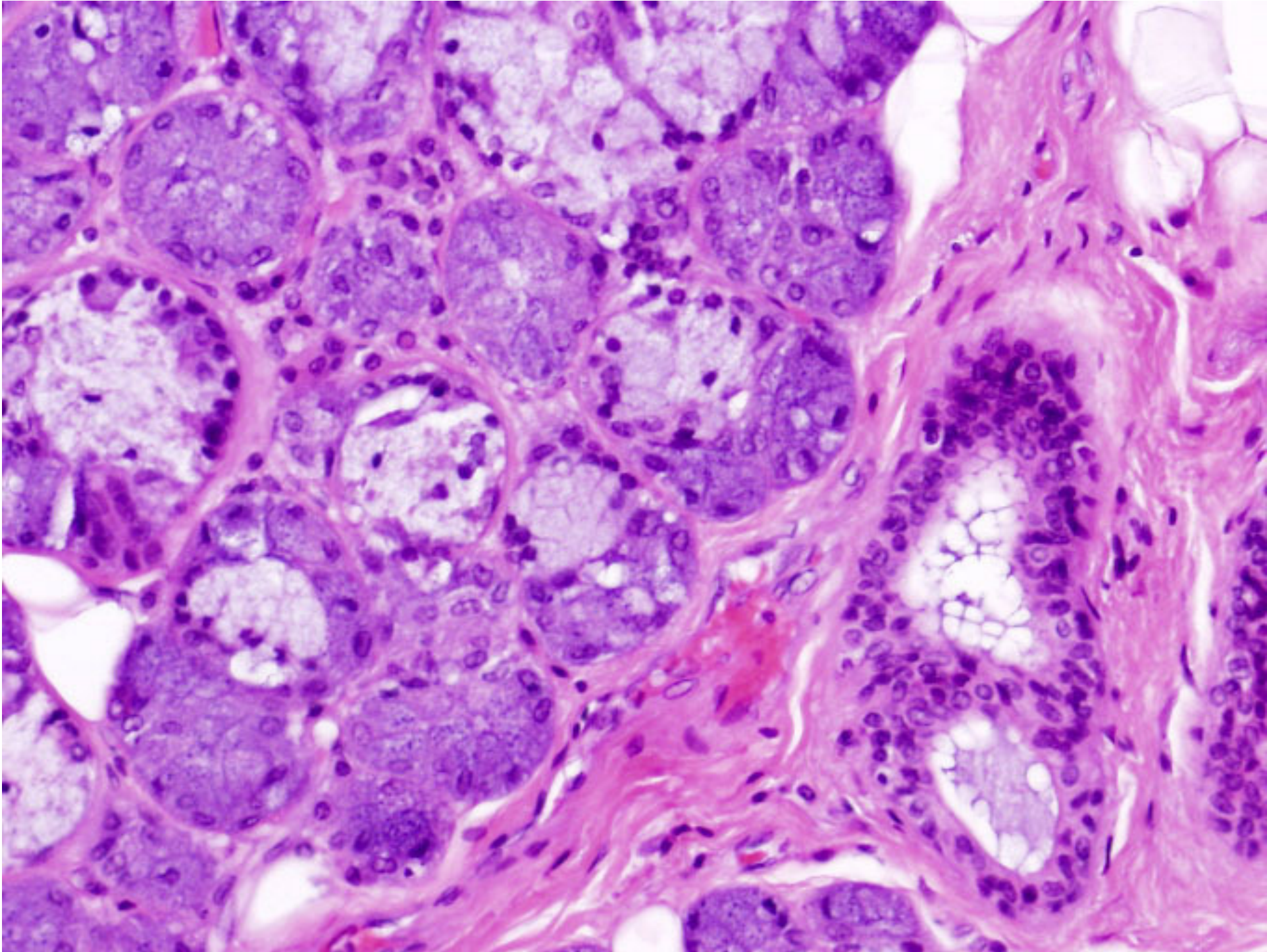


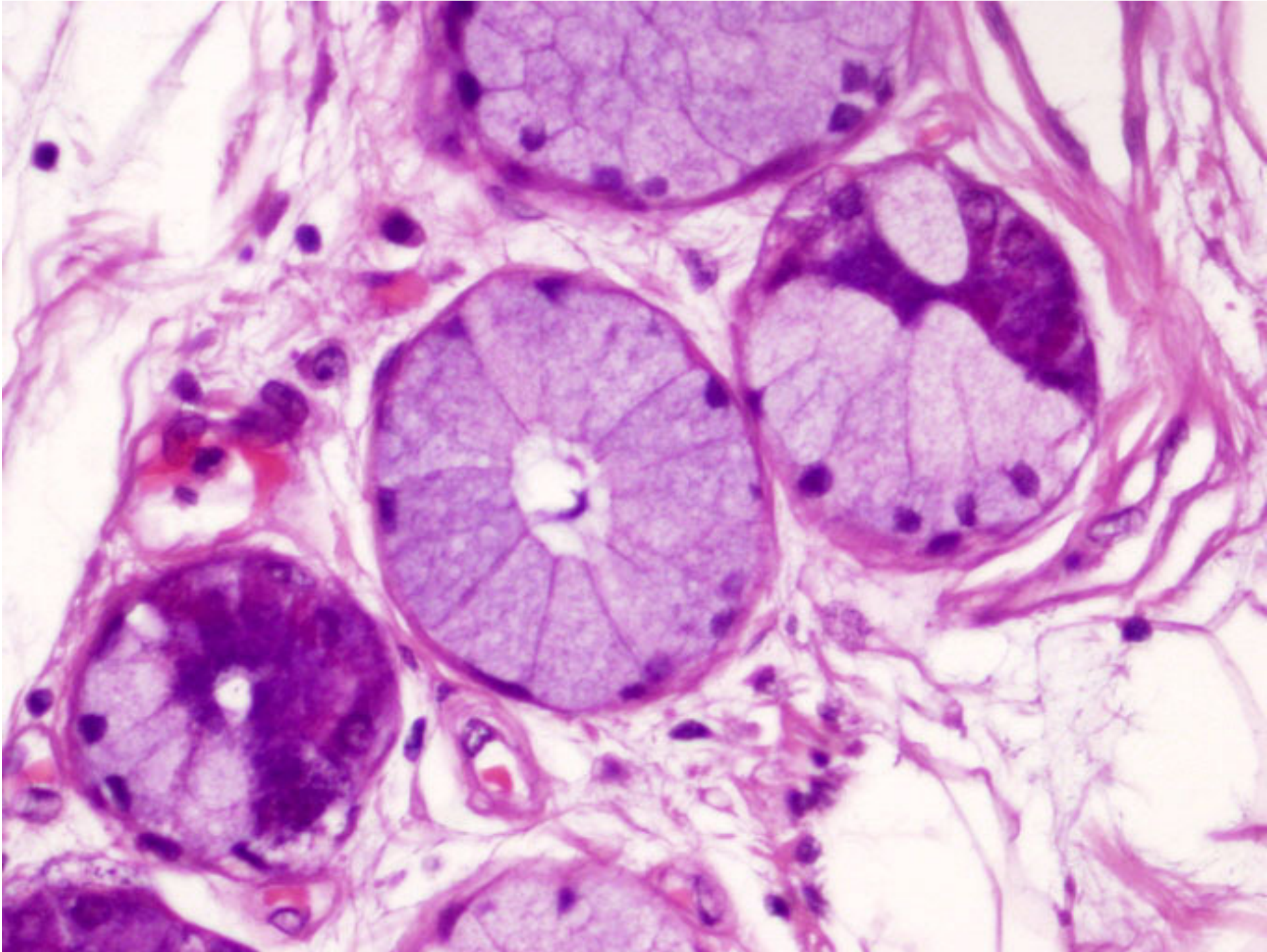
ANATOMIA PATOLOGICA
FACULTAD DE MEDICINA



ANATOMÍA PATOLÓGICA



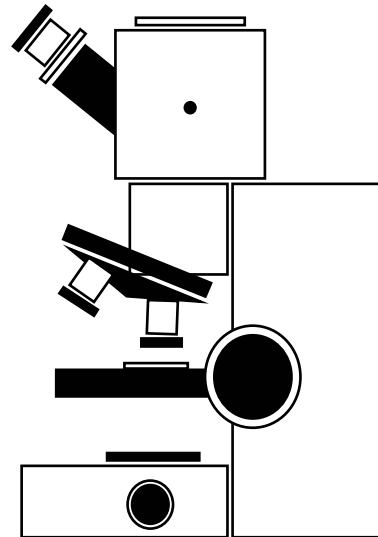




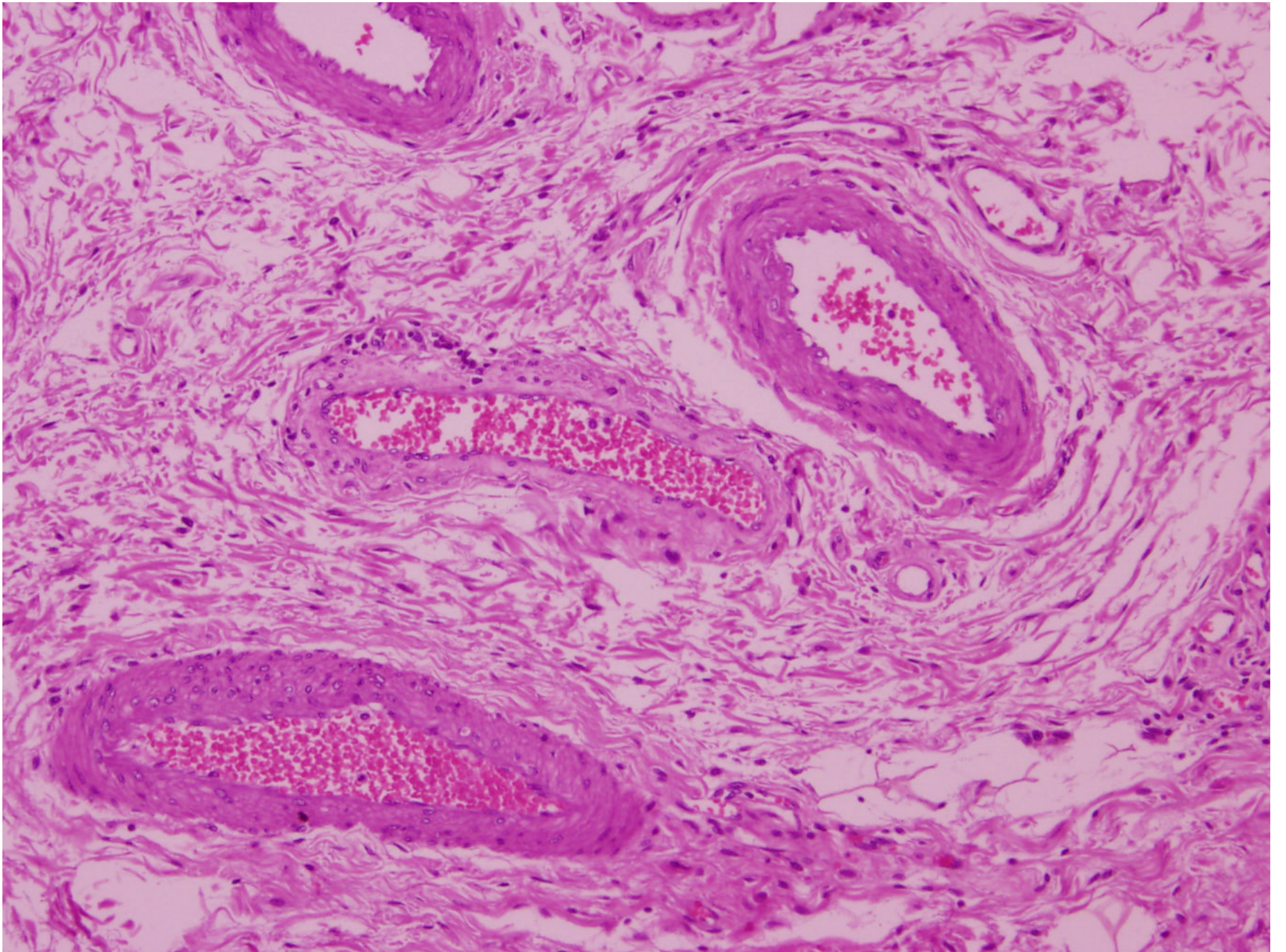
ATLAS DE MICROSCOPIA VASOS

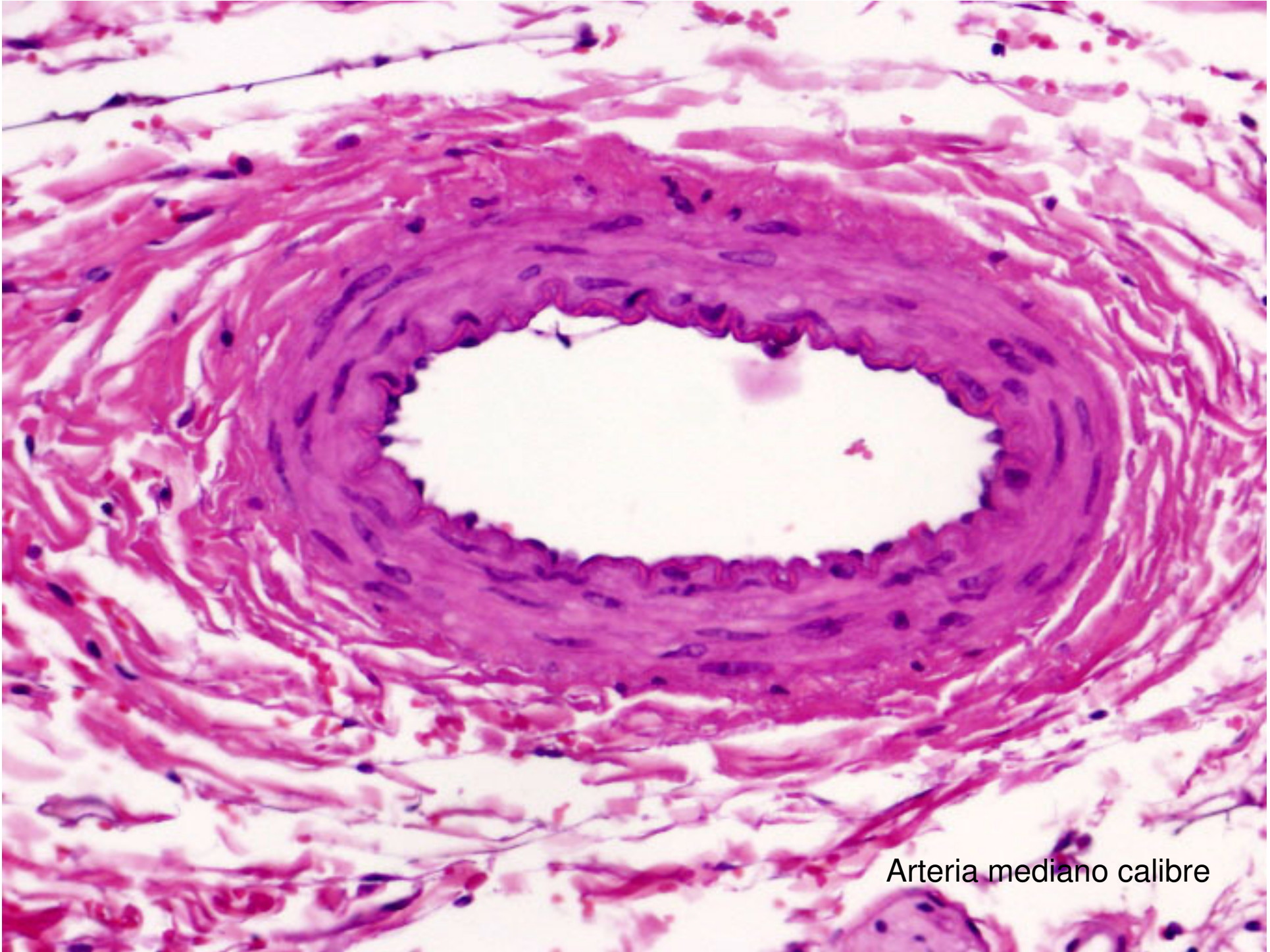


ANATOMIA PATOLOGICA
FACULTAD DE MEDICINA

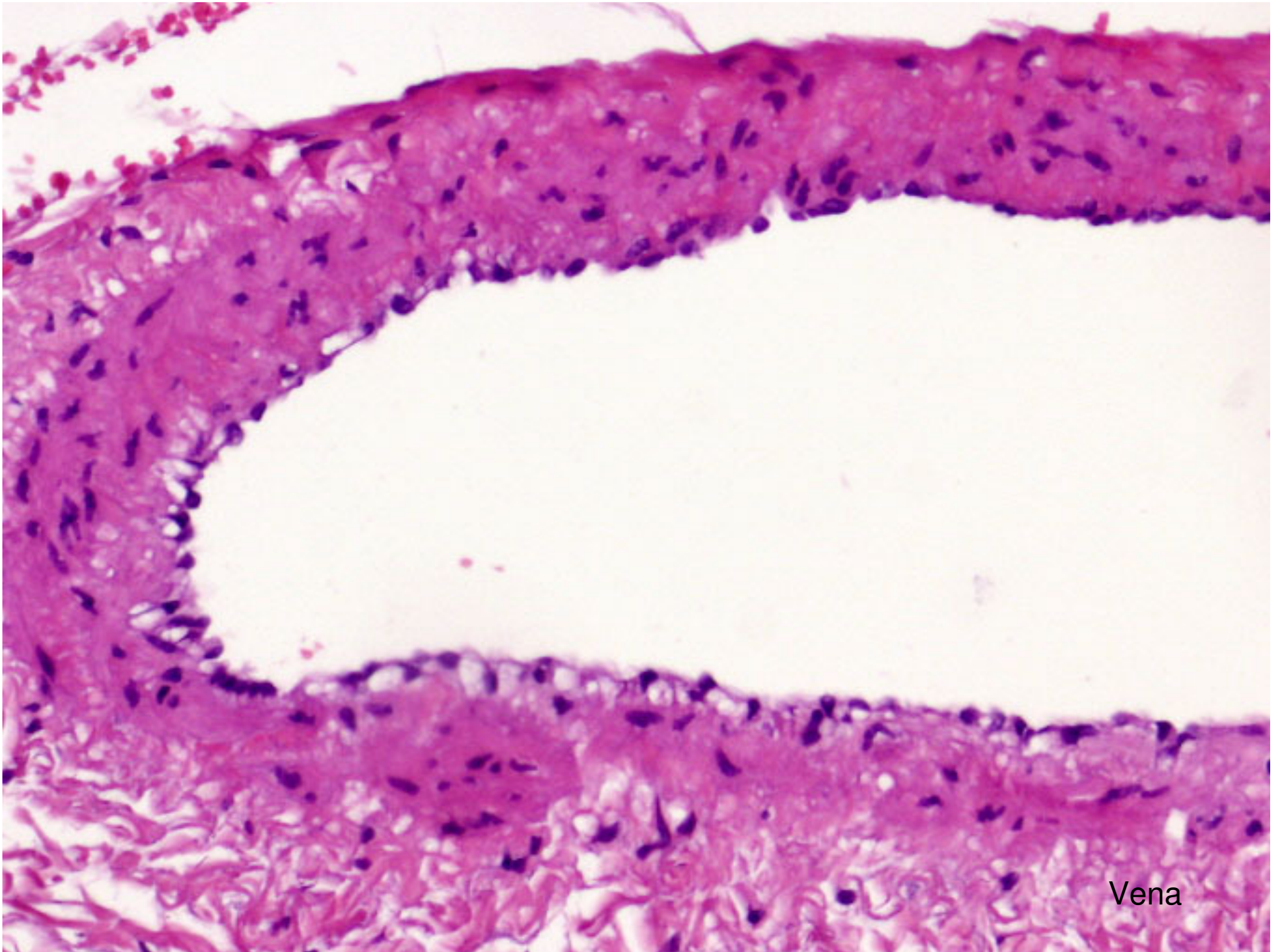


ANATOMÍA PATOLÓGICA

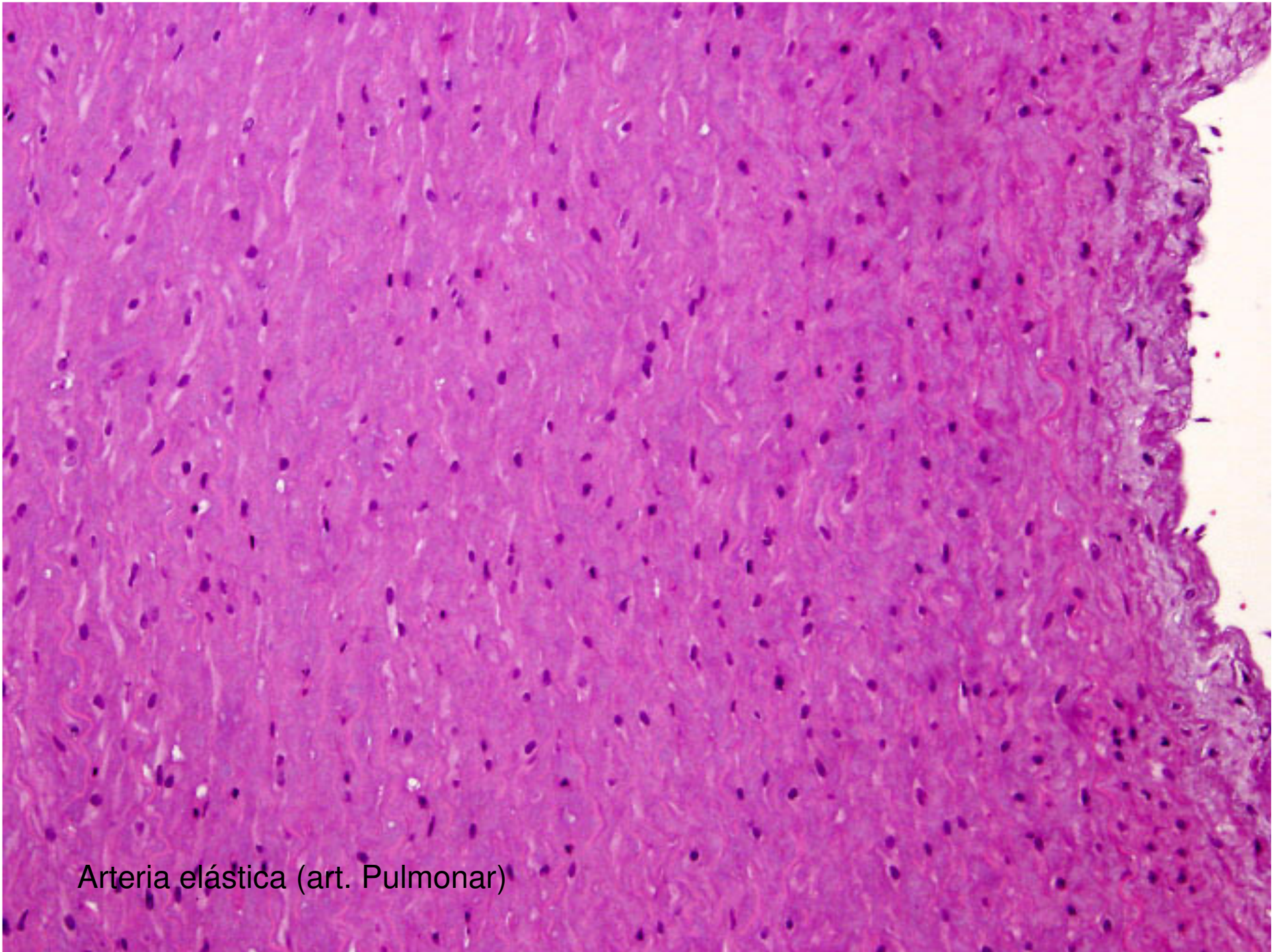




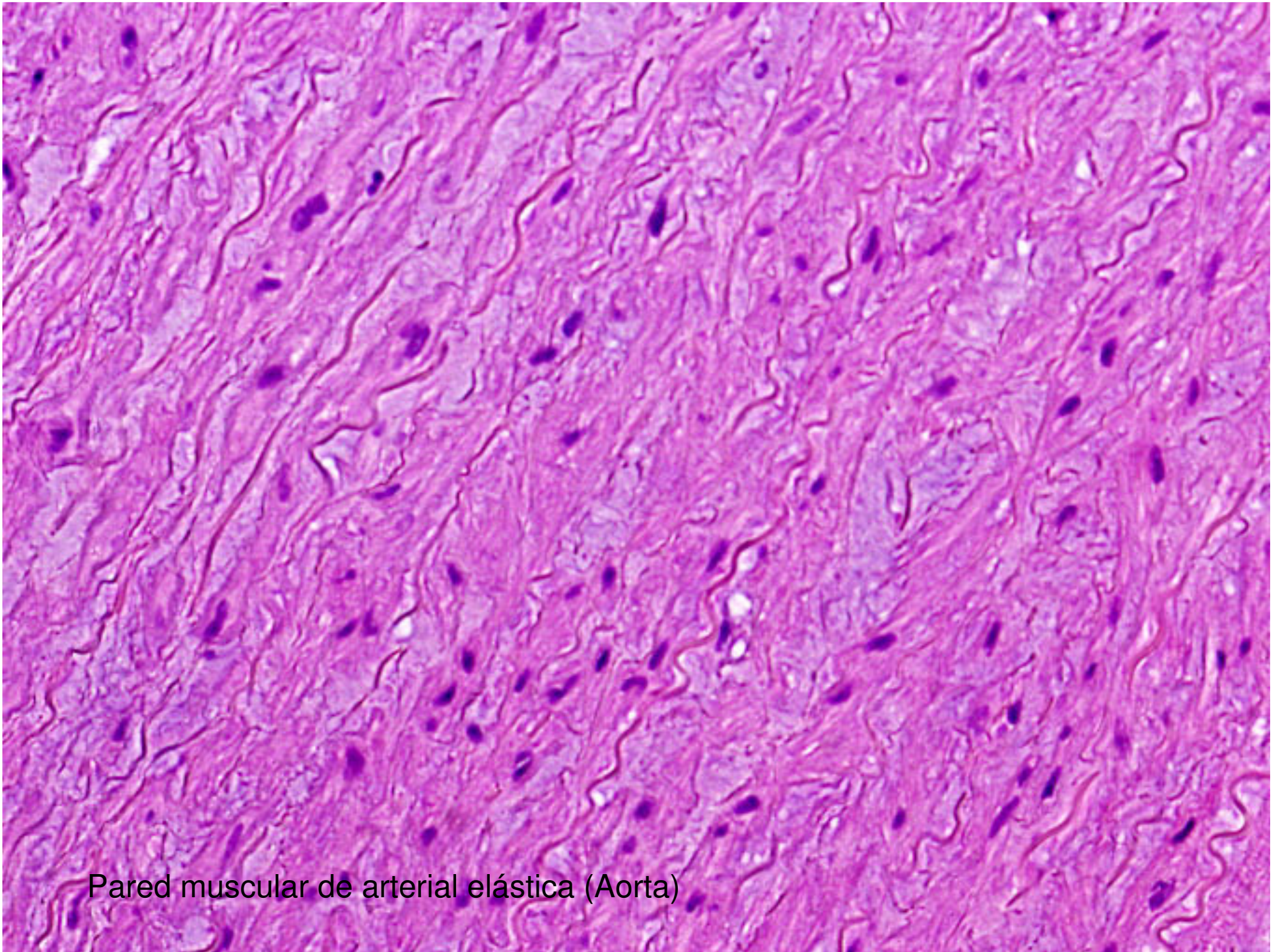
Arteria mediano calibre



Vena



Arteria elástica (art. Pulmonar)

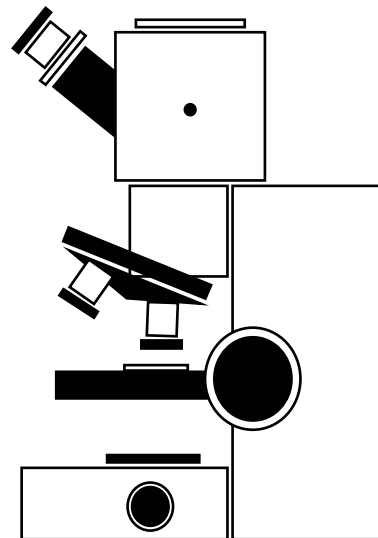


Pared muscular de arterial elástica (Aorta)

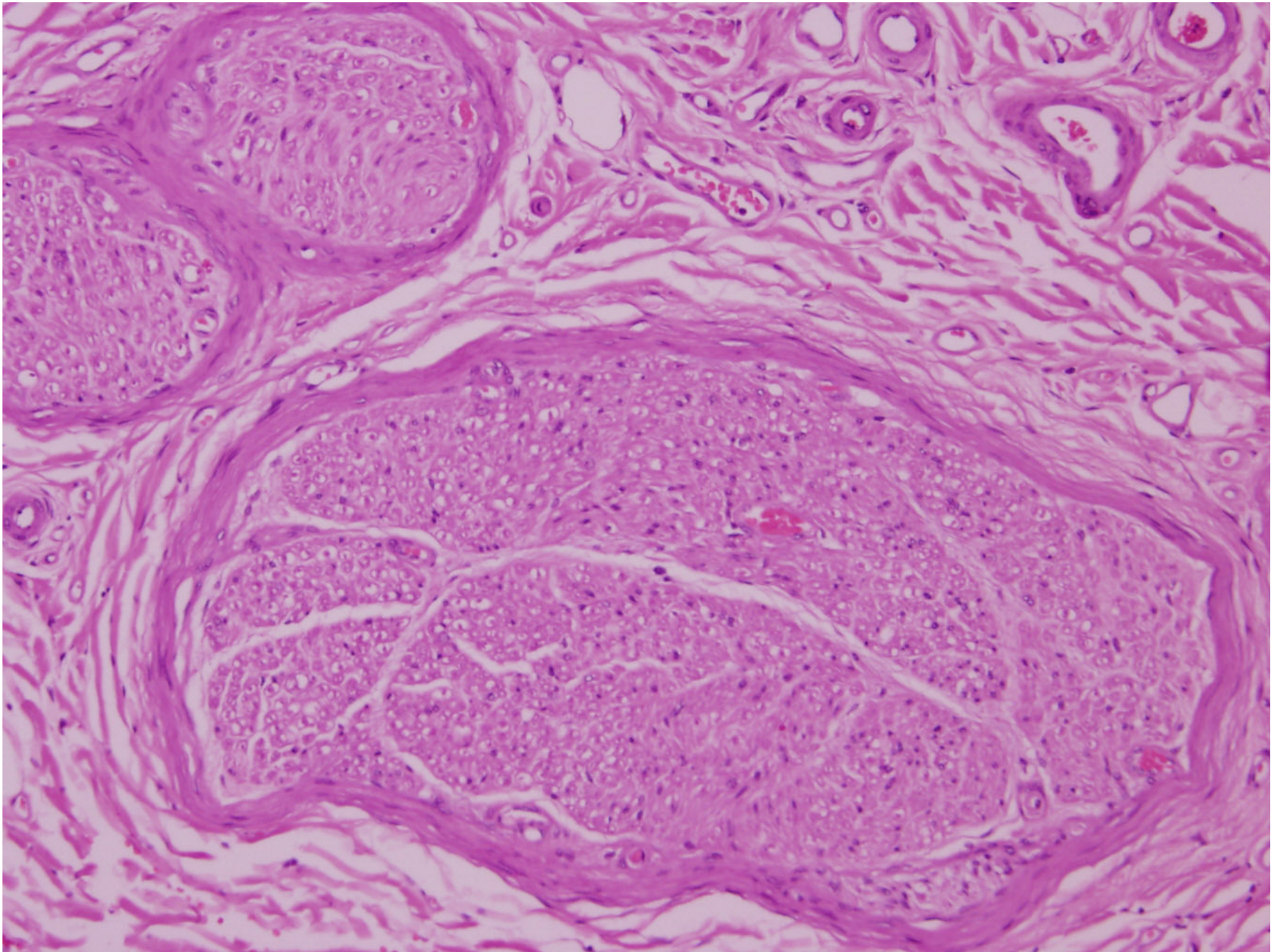
ATLAS DE MICROSCOPIA NERVIOS PERIFÉRICOS



ANATOMIA PATOLÓGICA
FACULTAD DE MEDICINA



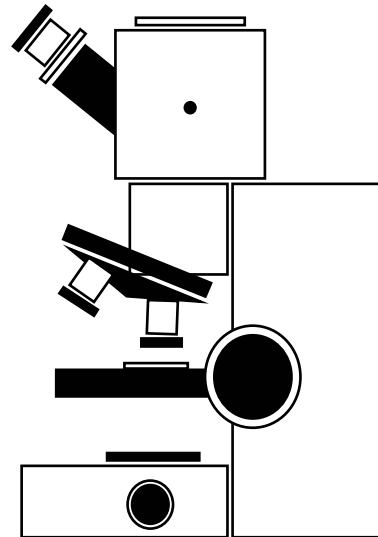
ANATOMÍA PATOLÓGICA



ATLAS DE MICROSCOPIA SNC

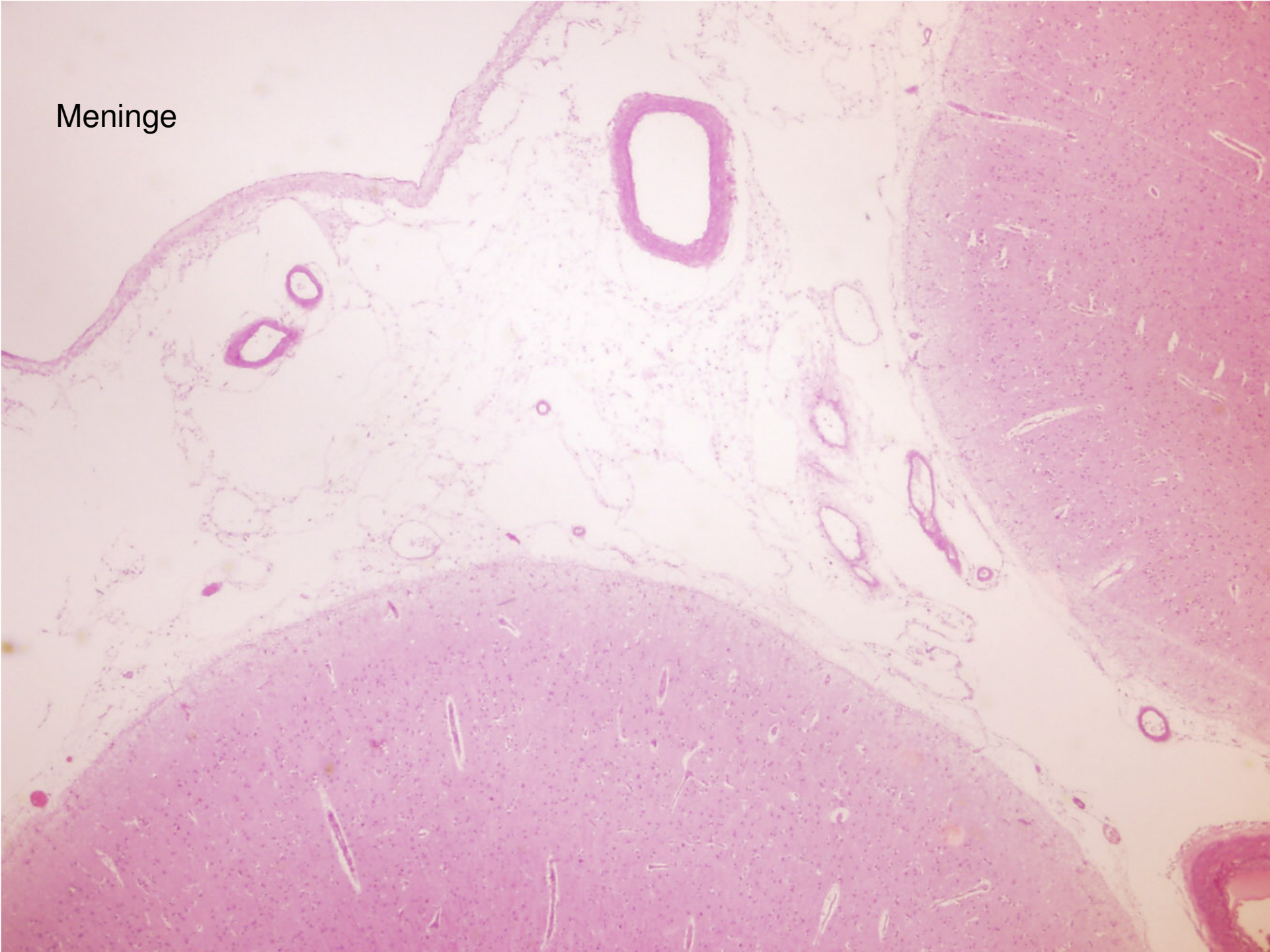


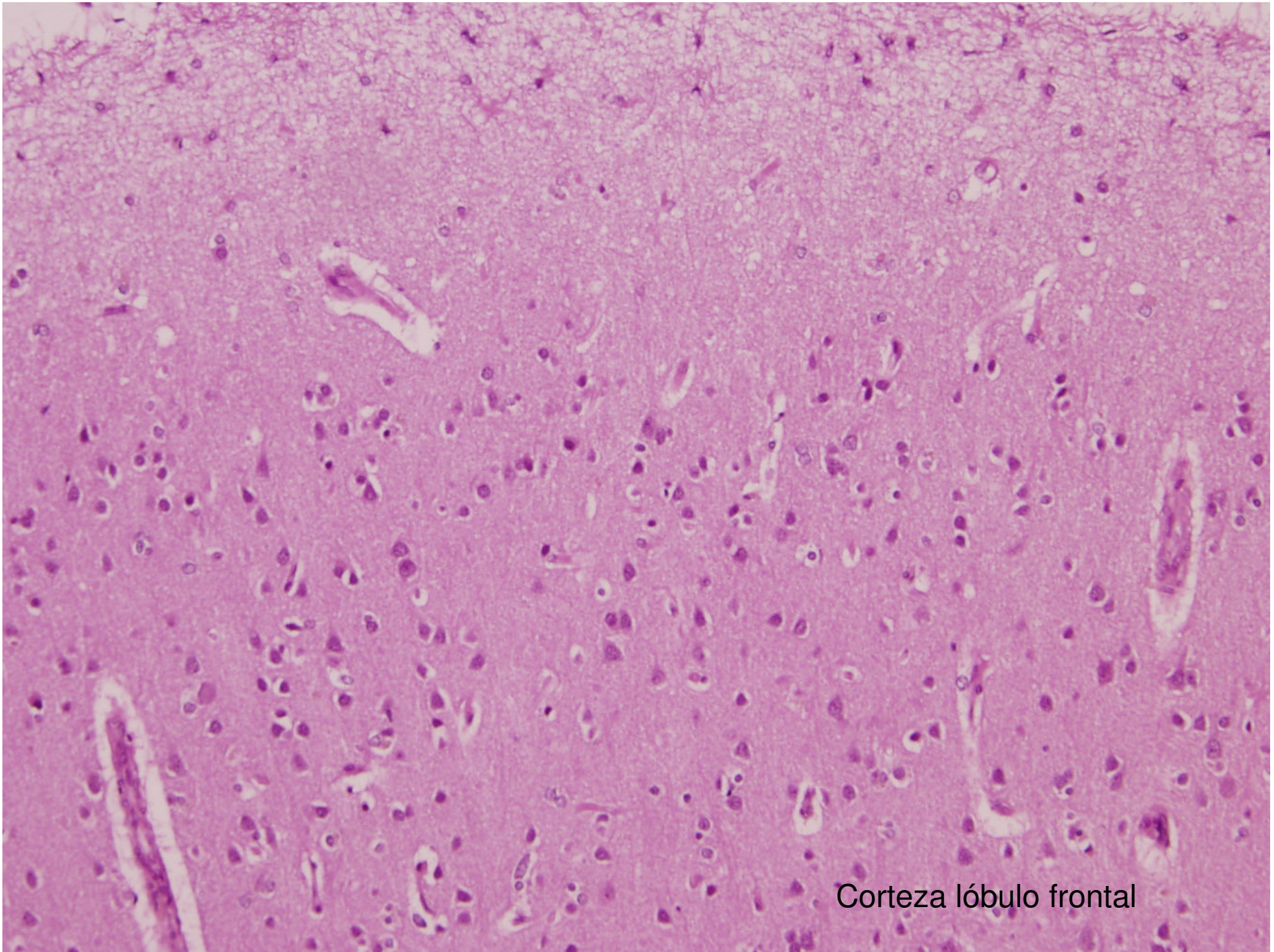
ANATOMIA PATOLOGICA
FACULTAD DE MEDICINA



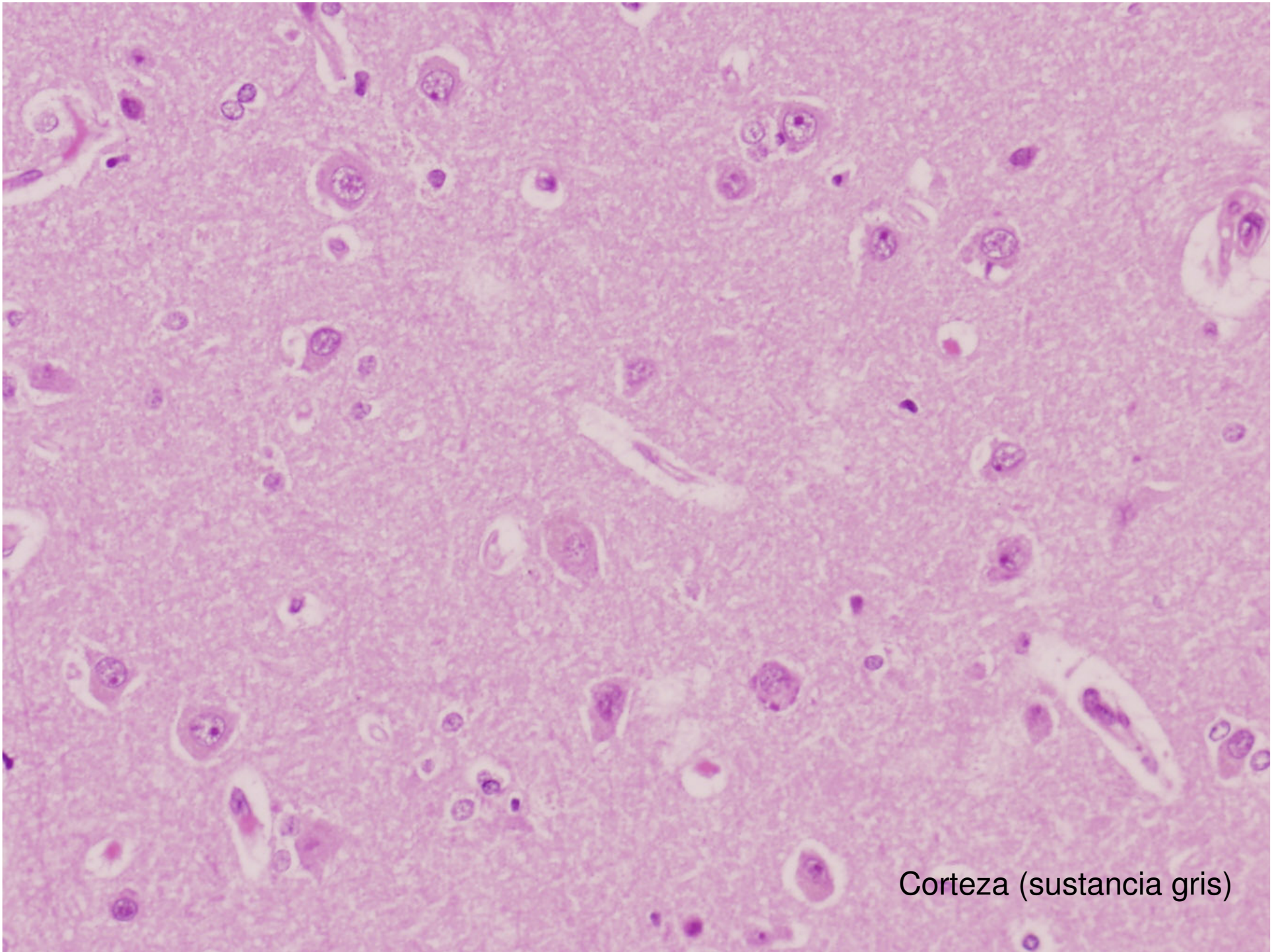
ANATOMÍA PATOLÓGICA

Meninge

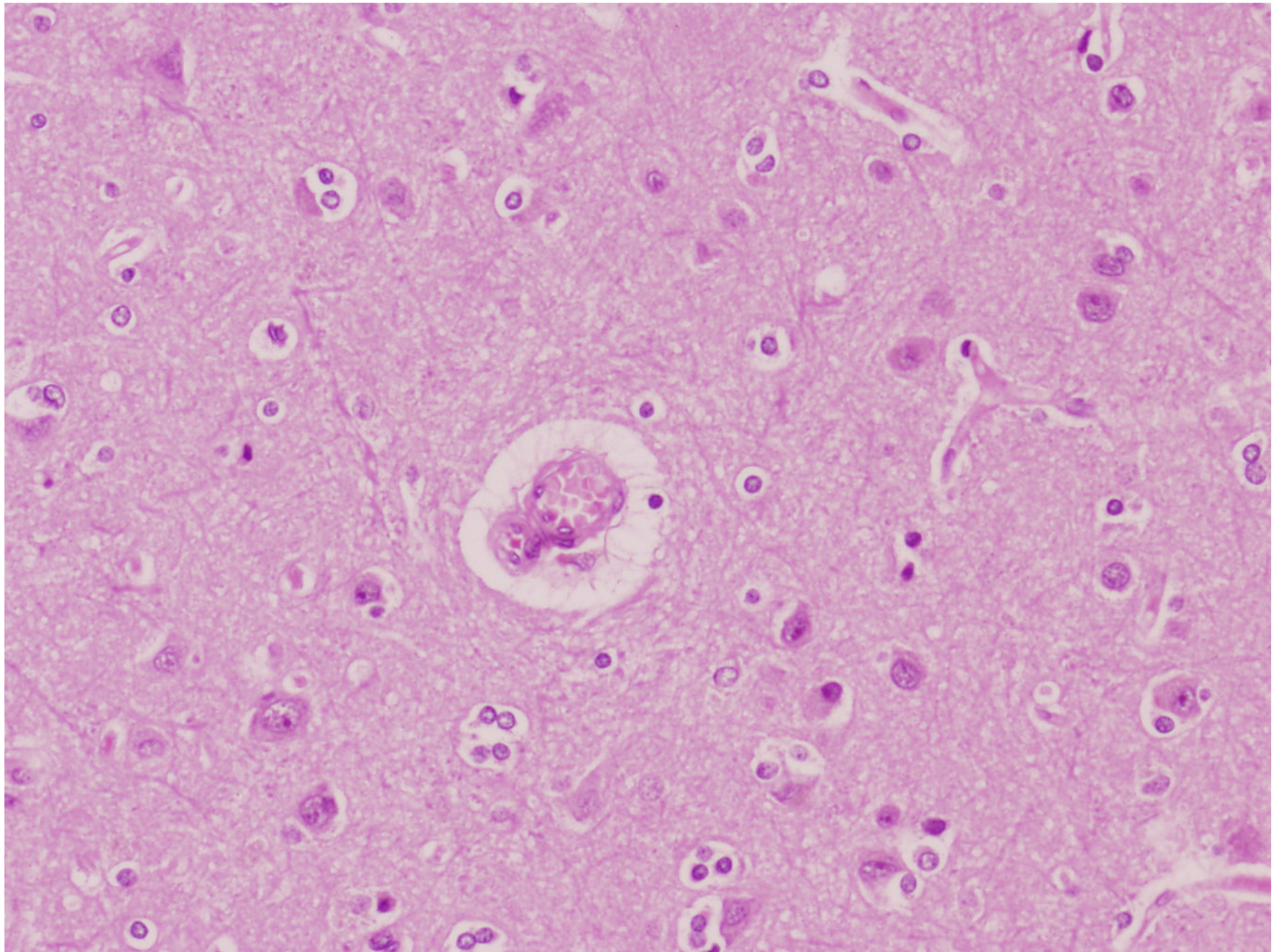


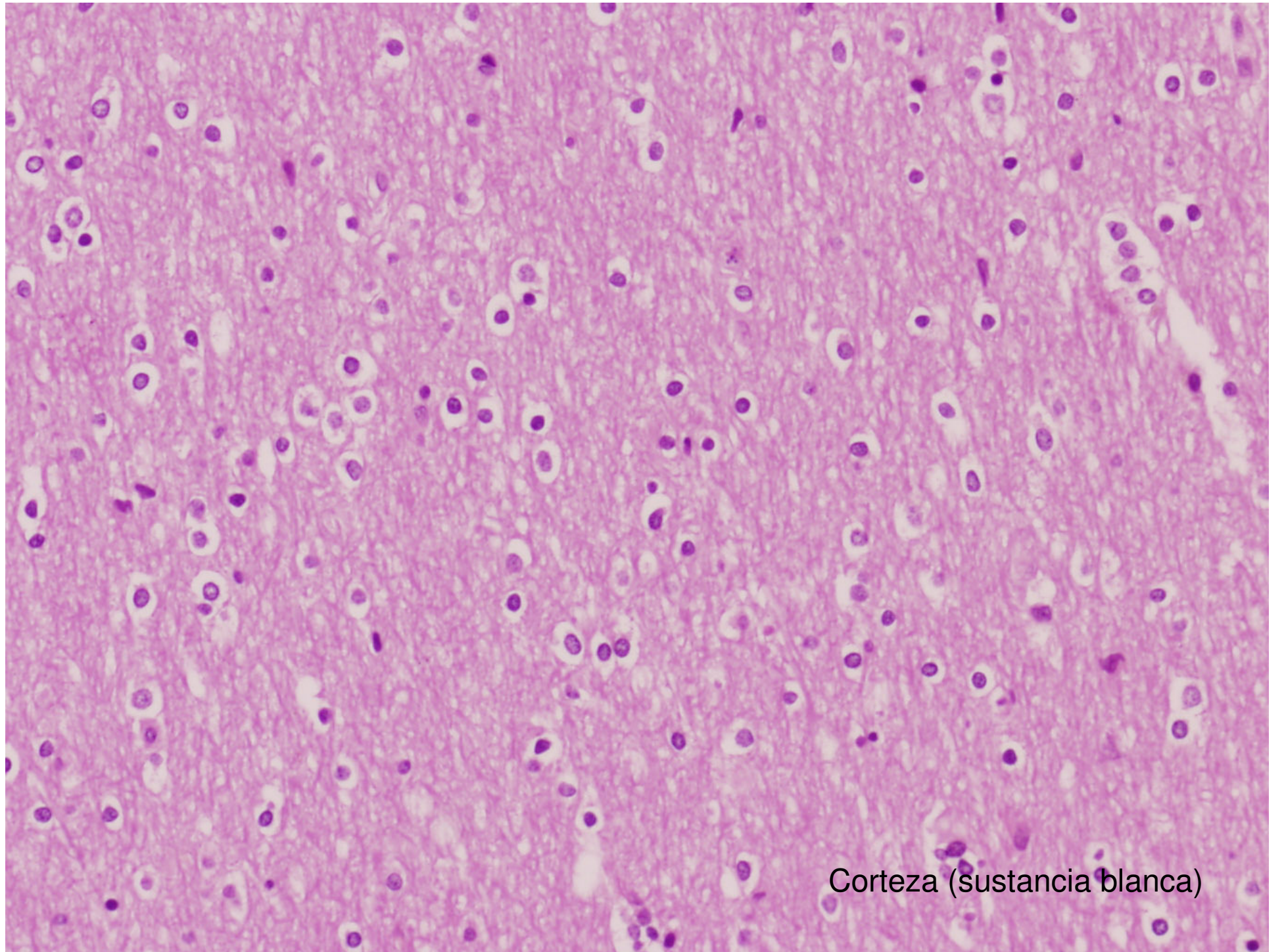


Corteza lóbulo frontal



Corteza (sustancia gris)

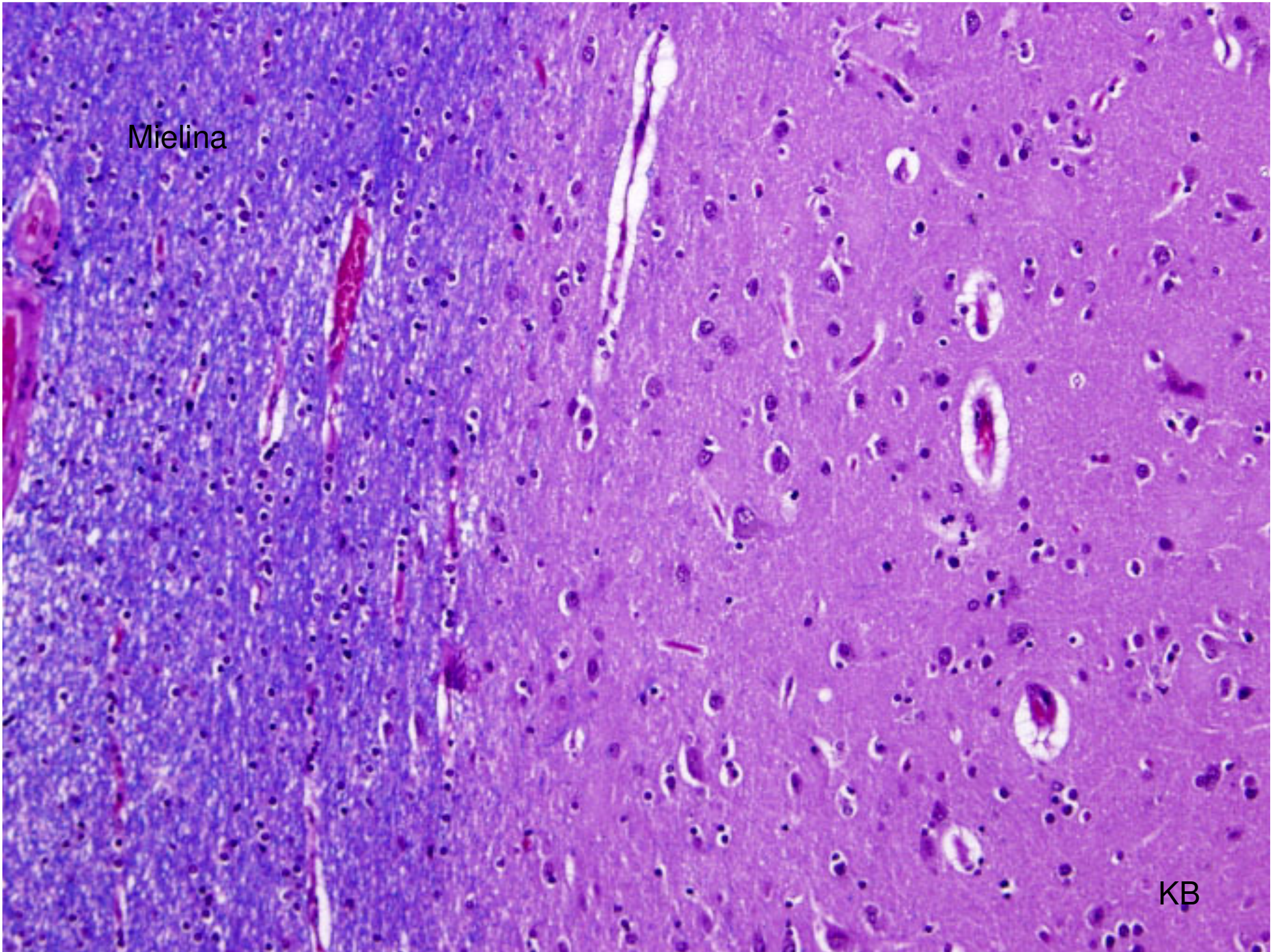




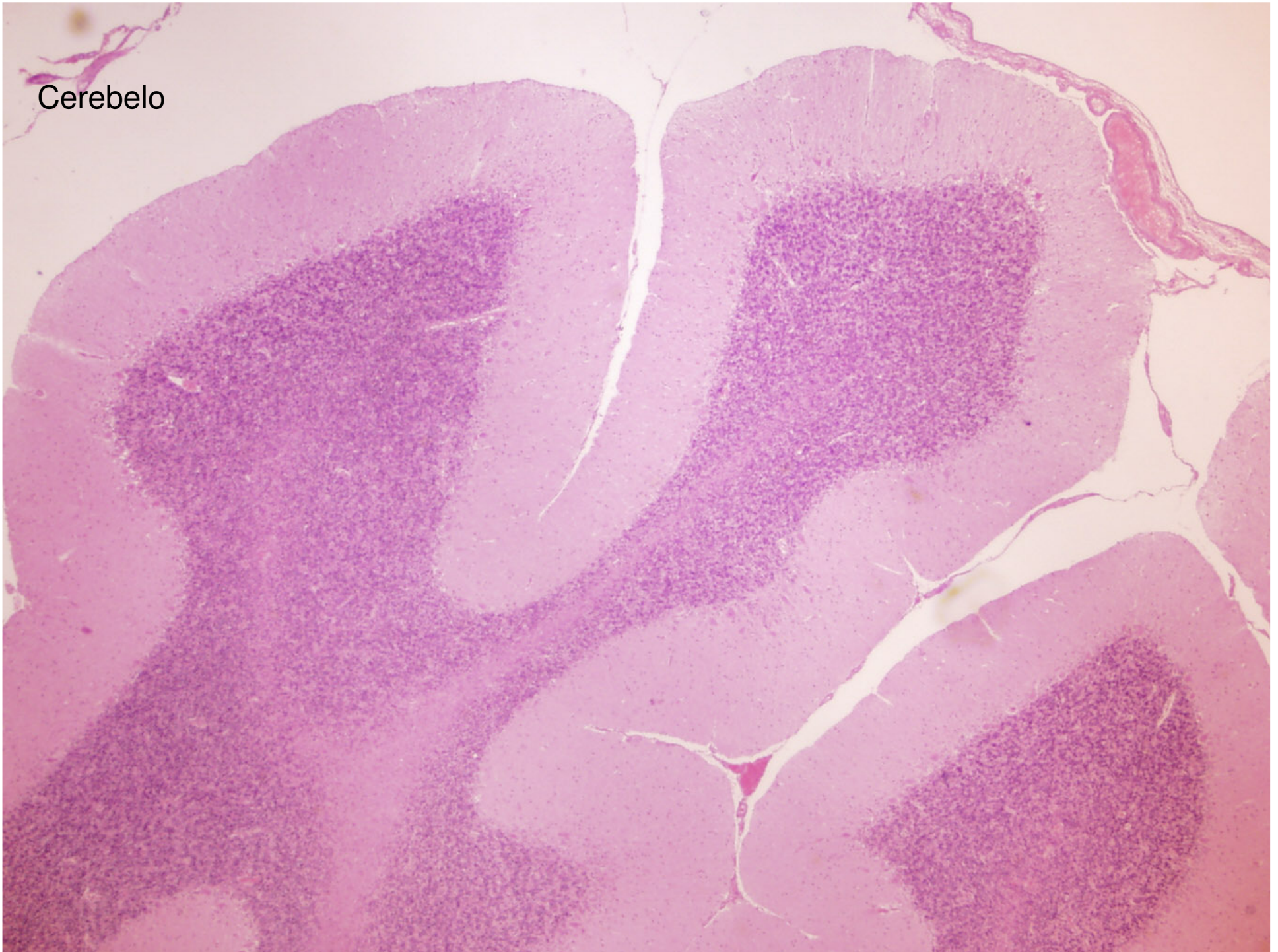
Corteza (sustancia blanca)

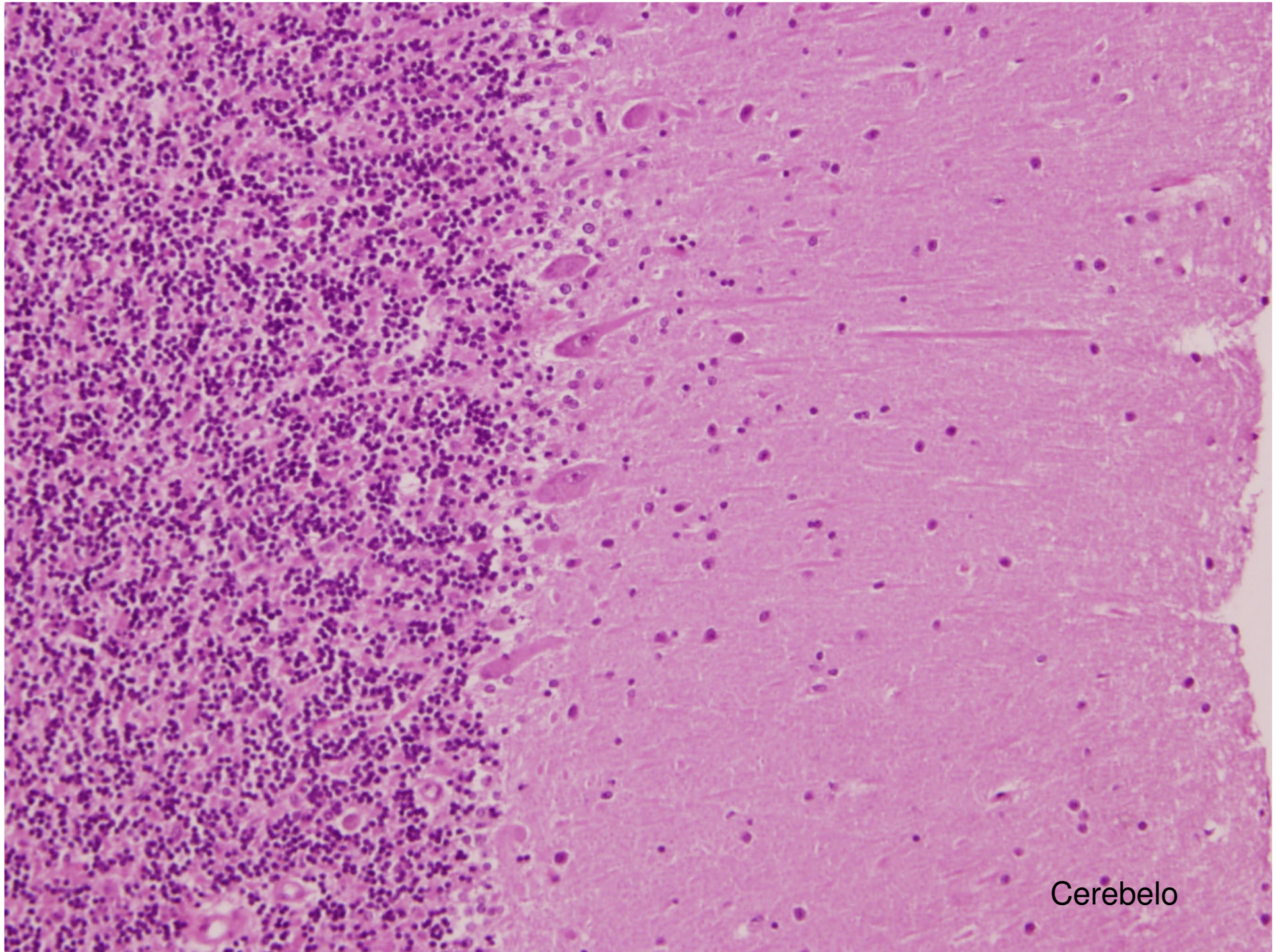
Mielina

KB



Cerebello





Cerebello